

6-1-2012

Identification of the Mandibular Nerve with CBCT Using a Nerve Marking Tool or Not

Myung Soo Choi
Loma Linda University

Follow this and additional works at: <http://scholarsrepository.llu.edu/etd>

 Part of the [Periodontics and Periodontology Commons](#)

Recommended Citation

Choi, Myung Soo, "Identification of the Mandibular Nerve with CBCT Using a Nerve Marking Tool or Not" (2012). *Loma Linda University Electronic Theses & Dissertations*. Paper 161.

This Thesis is brought to you for free and open access by TheScholarsRepository@LLU: Digital Archive of Research, Scholarship & Creative Works. It has been accepted for inclusion in Loma Linda University Electronic Theses & Dissertations by an authorized administrator of TheScholarsRepository@LLU: Digital Archive of Research, Scholarship & Creative Works. For more information, please contact scholarsrepository@llu.edu.

LOMA LINDA UNIVERSITY
School of Dentistry
in conjunction with the
Faculty of Graduate Studies

Identification of the Mandibular Nerve with CBCT
Using a Nerve Marking Tool or Not

by

Myung Soo Choi

A thesis submitted in partial satisfaction of
the requirements for the degree
Master of Science in Periodontics

June 2012

© 2012

Myung Soo Choi
All Rights Reserved

Each person whose signature appears below certifies that this thesis in his/her opinion is adequate, in scope and quality, as a thesis for the degree Master of Science.

_____, Chairperson
Jeffrey Henkin, Associate Professor and Program Director of Periodontics

Joseph M. Caruso, Associate Professor and Chair of the Department of Orthodontics and Dentofacial Orthopedics

Bernard Gantes, Associate Professor, Advanced Education in Periodontics

Yoon Jeong Kim, Associate Professor of Periodontics

ACKNOWLEDGEMENTS

I would also like to express my appreciation to my guidance committee, Dr. Jeffrey Henkin, Dr. Bernard Gantes, Dr. Joseph Caruso, and Dr. Yoon Jeong Kim for their advice and direction.

I would like to express my deepest gratitude to Dr Crigger who has provided me guidance for this research project. Additional thanks to Dr. Matt Riggs for statistical analysis.

And finally, I would like to thank God for providing me the undeserved opportunity to study His creation and marvel in its complexity.

CONTENTS

Approval Page.....	iii
Acknowledgements.....	iv
Table of Contents.....	v
List of Tables	vi
List of Figures.....	vii
List of Abbreviations	viii
Abstract.....	ix
Chapter	
1. Introduction.....	1
2. Materials and Methods.....	4
Patient selection	4
CBCT scanner.....	4
Viewing software program	4
Mandibular nerve location using the Simplant Nerve Marking Tool	5
Prints	5
Coronal view categories.....	5
Measurements	6
Unmarked prints.....	
Marked prints	
Suspected mandibular nerve location diameter	
Statistical analysis.....	8
3. Results.....	9
4. Discussion.....	15
5. Conclusion	17
References.....	18

TABLES

Table	Page
1. Scan coronal views distribution by categories.....	10
2. Distribution of the vertical mandibular canal measures for ES by categories.....	10
3. Levene's Test for Equality.....	11
4. ES minus ERT mm difference by category	12
5. ES minus IRT mm difference by category	13

FIGURES

Figure	Page
1. Coronal view morphology categories	6
2. Measurements	8
3. Example of a categories 3 coronal view	8
4. ES, IRT and ERT graphic representations of the suspected mandibular nerve	14

ABBREVIATIONS

CBCT	Cone Beam Computed Tomography
IAC	Inferior Alveolar Canal
IAN	Inferior Alveolar Nerve
NMT	Nerve Marking Tool
ERT	Experienced Radiology Technician
IRT	Inexperienced Radiology Technician
ES	Experienced Surgeon

ABSTRACT OF THE THESIS

Identification of the Mandibular Nerve with CBCT Using a Nerve Marking Tool or Not

by

Myung Soo Choi

Master of Science Graduate Program in Periodontics
Loma Linda University, June 2012
Dr. Jeffrey Henkin, Chairperson

Introduction: In the field of implant dentistry, cone beam computed tomography can give clinicians valuable information regarding anatomic structures, bone quantity and quality. If the mandibular nerve is encroached during surgery, severe morbidity of the patient and medico-legal issues may result. Thus the importance of accurate determination of the position of mandibular canal cannot be overemphasized.

Purpose: The aim of this study is to evaluate the difference in the position of the mandibular nerve determined, and marked by a radiology technician utilizing nerve marking tool and compared to the same measurement by a clinician not utilizing a nerve marking tool.

Materials and Methods: With ninety six consecutive CT scans taken by CB MercurRay for dental implants, the location of the nerve canal was marked with a nerve marking tool by both an experienced and inexperienced radiology technician each using the Simplant program from Materialise. The marked coronal image was printed on paper along with unmarked axial image, the distance between the film frame reference line to the superior border of canal and between the film frame reference line to the inferior border of the mandible was measured in all marked and unmarked printed images and the

distance between the superior border of the canal to the inferior border of the canal in unmarked prints was also measured by one experienced surgeon.

Results: The distance from the inferior border of mandibular canal to the inferior border of the mandible is 7.1 ± 1.8 mm, for the ES, 8.0 ± 2.1 mm, for the ERT, and 8.0 ± 2.2 mm for the IRT. There were no significant differences between these means \pm SD. The measurement of the distance from the superior border of mandibular canal to the inferior border of the mandible is 14.2 ± 2.1 mm for ES, 11.0 ± 2.1 mm for the ERT, and 11.0 ± 2.2 mm for the IRT. The comparison of ERT to IRT would prove insignificant; however, the contrast between the ES versus the ERT, as well as, ES versus the IRT would prove highly significant ($p < 0.001$).

Conclusion: There are differences between the position of the superior border of the mandibular canal determined by an experienced surgeon without utilizing a nerve marking tool and by radiology technician who utilized a nerve marking tool. Implant surgeons should interpret with caution the determined position of the mandibular canal with nerve marking tool performed by a radiology technician, and should always consider anatomic variation of the nerve.

Key Words: Cone beam Computed Tomography, Inferior Alveolar Canal, Inferior Nerve, Nerve Marking Tool, Axial view categories

CHAPTER ONE

INTRODUCTION

Clinical identification of the inferior alveolar canal (IAC) and its content is essential prior to dental implant related osteotomy preparation in order to preserve the integrity of the inferior alveolar nerve (IAN), along with accompanying artery and vein. Encroachment and invasion of the roof of the IAC, causing traumatic injury to the neurovascular bundle enclosed within, can result in permanent damage to the patient, including paresthesia to the lower lip, mucosal and gingival tissues enervated by the terminal incisal nerve. In addition to the unfortunate sensory loss of function experienced to the patient, the clinician may be subject to judicial financial reparation.

Effective clinical identification of the IAC is dependent upon an accurate understanding of the anatomical configuration of the canal and its content. Much of the existing IAN course has been obtained by gross surgical dissection.¹⁻⁷ There is general consensus that the neurovascular bundle varies as to its anterior-posterior position extending from the third molar site through its exit via the mental foramen. The IAC is seen often as a single tube having its periphery made of denser bone, sometimes as two tubes, demonstrating a superior and inferior position. Frequently, in addition to the inferior tube, a plexus of branching occurs superiorly to the IAC. Several dissection studies have diagramed the various nerve branch configurations.^{1-3,7} In addition to an explanation of the neurovascular pathway, dissection has reported the average vertical diameter of the IAC to be between 2.5 to 3.0 mm.^{4,8} Vertical measurement of the

distance from the inferior border of the mandible extending to the inferior border of the IAC was found to approximate 10 mm, varying as to the anterior to posterior position within the mandible.^{4,8,9}

The variations of the IAN make clinical identification difficult. Historically, two-dimensional radiographs were employed for this purpose. Several of the dissection studies compared the cadaver anatomic information with their accompanied routine lateral radiographs.^{1,3,7,8} All of the investigators expressed an inability to confirm the gross visual distribution of the neurovascular material on the radiographic survey. A single tubular expression was the pattern most likely identified, particularly when the IAC was located near the lingual cortical plate or was associated with a lingual cortical wall depression. They all mentioned difficulty in identifying branching or even the presence of cortical rather than trabecular bone.

The advent of cone beam computed tomography (CBCT) for the dental field has enabled a three-dimensional volumetric visualization for clinical analysis of mineralized tissues. Angelopoulos¹⁰ reported an enhanced identification of the IAC with the aid of the CBCT relative to a standard panoramic radiograph. Others have demonstrated variation among evaluators, particularly when confined to using a single tomographic slice. Multiple formatted views appeared to facilitate the clarity of the identification.^{11,12}

Several software companies specializing in CBCT imaging are proposing virtual treatment modules for implants as well as nerve marking tools to assist the clinician in decision making for implant placement in the posterior mandible regions. Many busy clinicians rely on radiology technicians to mark the nerve allowing them to analyze the scan faster.

The lack of consistency and the lack of available clinical material using the CBCT in determining the clinical position of the IAN would suggest a need to enhance our efforts to better define the pre-surgical capability of this device. Consequently, this study was undertaken to analyze a large sample of CBCT scans utilized to determine the position of the suspected IAN prior to insertion of dental intraosseous implants. The same sample utilized a nerve marking tool using a leading treatment software program, Simplant by Materialize. Differences in locating the mandibular nerve using a nerve marking tool and without the nerve marking tool were analyzed.

CHAPTER TWO

MATERIALS AND METHODS

Patient Selection

Ninety six consecutive clearly readable scans from patients seeking implant reconstruction in the posterior mandible at a private practice of a Loma Linda University School of Dentistry clinical instructor off-site facility were selected. Inclusion criteria required each subject to have at least one missing tooth in the premolar or molar region.

CBCT Scanner

All the scans were acquired using a CB MercuRay (12 bit; Hitachi Medical Corporation, Twinsburg Ohio) using the P-mode (9" diameter; 100 kVp; 15 mAs). Patient's heads were positioned enabling a horizontal occlusal plane with reconstruction.

Viewing Software Program

All the DICOM data was imported into the Simplant auto-formatting program (Materialise Ann Arbor, MI). On an axial slice at the level of the mandibular roots, a reference curve was drawn in the middle of the edentulous ridge on the posterior edentulous regions. The reference curve continued forward of the mental foramen. Numbered cross-sectional coronal images were automatically reconstructed by the software.

Mandibular Nerve Location Using the Siplant Nerve Marking Tool (NMT)

Using the NMT, the location of the nerve canal was underlined in color by either an experienced radiology technician (ERT) having had five years practice, and an inexperienced radiology technician (IRT) having had only one demonstration of the nerve marking tool. The two technicians accomplished their marking independently by utilizing two differentiating colors.

Prints

Three separate sets of glossy paper prints using a 1:1 ratio were created. The prints from the two technicians, ERT and IRT were printed using different colors for the marked nerve. The third set of prints that were unmarked (UP) were produced allowing for nerve identification by an experienced surgeon (ES), with twenty eight years of practice using computed tomography.

Coronal View Categories

The ES divided the spectrum of scans into seven sub-grouping categories based upon gray scale gross morphology as follows:

Category 1. One circular well differentiated radio dense mandibular canal like structure.

Category 2. Two independent circular well differentiated radio dense mandibular canals.

Category 3. One circular well differentiated radio dense mandibular canal like structure in addition to multiple poorly differentiated radiolucent small circular structures coronal to the canal like structure.

Category 4. Multiple bundles of poorly differentiated radiolucent small circular

structures.

Category 5. Lower half of mandibular space exhibits no specific radiopaque structure.

Appears as a large radiolucent area.

Category 6. Poorly differentiated bundle of small circular structures being slightly more radio dense than the rest of the generally radiolucent mandible.

Category 7. No structure can be identified in the generally radiolucent mandible.

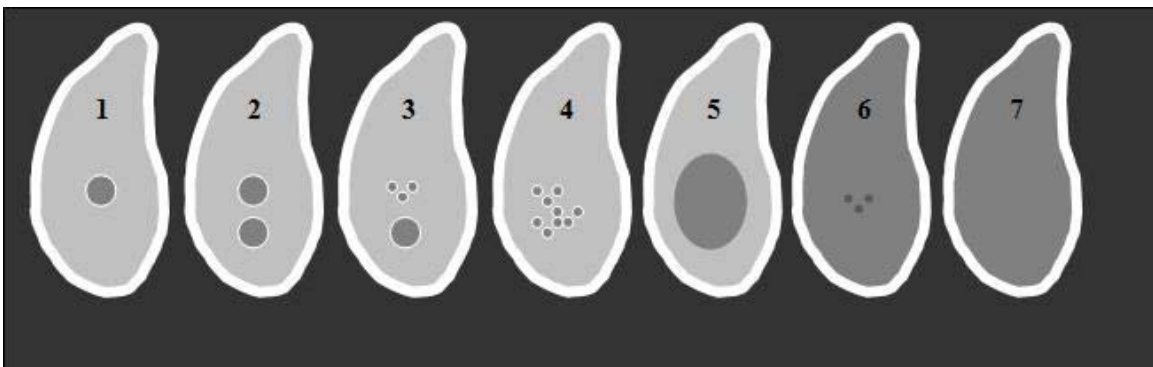


Figure 1: Coronal view morphology categories

Measurements

All measurements were made by the ES with a millimeter ruler, rounding to the closest millimeter. All the areas measured were the same area sagittally along the canal since a reference curve was drawn in the middle of the edentulous ridge on the posterior edentulous regions, and numbered cross-sectional coronal images were automatically reconstructed by the software.

Unmarked Prints

After sufficient observation and exploration of adjacent coronal slices distal and mesial beyond the mental foramen, the section of interest was assigned to a mandibular category number (1-7). The zero of a transparent ruler was placed on the coronal extend of the suspected IAN with the graduations directed towards the apex and parallel to the side of the frame. The apical extend of the “suspected” IAN location was noted. Without moving the ruler, the distance of the inferior border of the frame was noted and served as a fixed reference line. The distance between the inferior border of the mandible to the fixed reference line was noted as well.

Marked Prints

The same measurements were made by placing the zero of the ruler on the coronal border of the colored marked nerve.

Suspected Mandibular Nerve Location Diameter

The unmarked prints were analyzed as described above. The marked prints suspected mandibular canal diameters were all identical.

Superior border of the suspected mandibular canal to the inferior border of the mandible.

This value was calculated.

Inferior border of the suspected mandibular canal to the inferior border of the mandible.

This value was calculated.

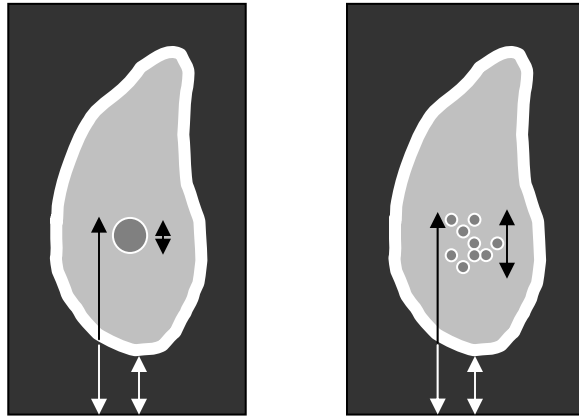


Figure 2: Measurements

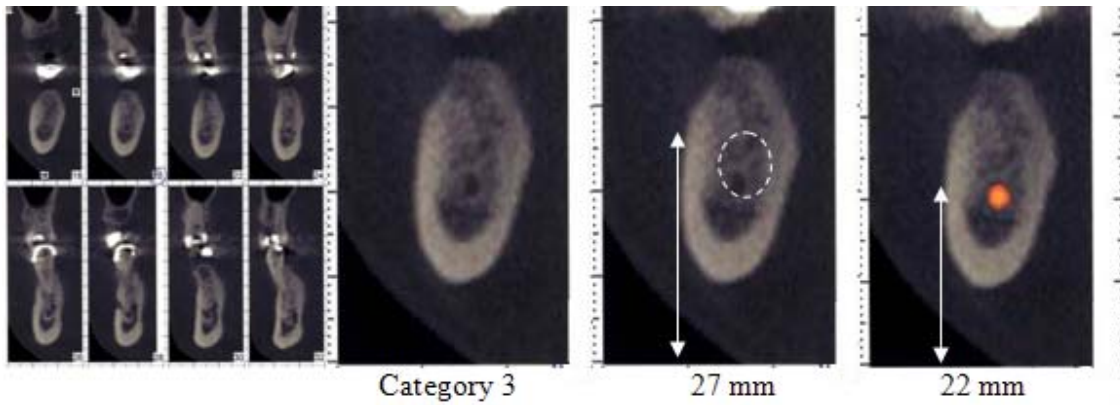


Figure 3: Example of a Category 3 coronal view

Statistical analysis

Since the scans were analyzed by mandibular morphology categories, smallness of the sample size per various category resulted in very low statistical power.

Nevertheless, analysis of variance with LSD multiple comparison was used to test for difference among all measurements acquired from each group.

CHAPTER THREE

RESULTS

Considering that the IRT and the ERT utilized by default a 3 mm diameter circular identifier, representing the position of the mandibular canal, the material for comparison between the experienced and inexperienced Technicians, were eventually contrasted with the experienced surgeon. This limited to the measurement of the inferior border of the mandibular canal extending to the inferior border of the mandible. Data reveals that this measure is 7.1 ± 1.8 mm, for the ES, 8.0 ± 2.1 mm, for the ERT, and 8.0 ± 2.2 mm for the IRT at premolar and molar area. There were no significant differences between them.

When the impact of the variables of subject and gender were examined no significant effect was noted. There was a modest and unexplained significance when the effect of age was evaluated. This presented as an inverse relationship, an increase in age resulted in a decrease in the inferior canal to mandibular border distance.

The most critically important anatomic landmark regarding implant placement would be the superior border of mandibular canal. This position is determined by adding the distance from the inferior border of the mandibular canal to inferior border of the mandible to the vertical diameter of the canal. Data reveals that this measure is 14.2 ± 2.1 mm for ES, 11.0 ± 2.1 mm for the ERT, and 11.0 ± 2.2 mm for the IRT. The comparison of ERT to IRT prove insignificant; however, the contrast between the ES versus the ERT, as well as, ES versus the IRT would prove highly significant ($p < 0.001$).

Comparing the results as they related to the seven subjective anatomic categories reduced the sample size to a level that prevented any meaningful statistical significance.

Table 1: Scan coronal views distribution by categories

Category	Sample size	Percent(%)
1	7	7.3
2	7	7.3
3	45	46.9
4	20	20.8
5	7	7.3
6	6	6.3
7	4	4.2

Table 2: Distribution of the vertical mandibular canal measures for ES by categories

Category	Sample size	Diameter(mm)
1	7	4.1 ± 1.7
2	7	7.4 ± 1.9
3	45	6.4 ± 1.4
4	20	7.3 ± 1.9
5	7	9.1 ± 2.9
6	6	9.2 ± 1.2
7	4	10.3 ± 3.3

Again, when assessing the critical position of the superior border of mandibular canal relative to the inferior border of the mandible, the following mm data recorded. The smallness of the various category numbers resulted in inadequate levels of power for statistical inference.

Table 3: Levene's Test for Equality

Category	Sample size	ES	ERT	IRT
1	7	12.9 ± 2.9	12.3 ± 2.6	12.3 ± 2.6
2	7	14.3 ± 2.6	12.0 ± 3.5	11.1 ± 3.8
3	45	14.0 ± 1.8	11.0 ± 1.6	10.9 ± 1.5
4	20	13.7 ± 2.5	10.1 ± 2.2	10.3 ± 2.3
5	7	16.1 ± 2.9	12.1 ± 3.5	12.0 ± 3.2
6	6	16.0 ± 2.3	10.2 ± 2.1	10.3 ± 1.6
7	4	14.0 ± 2.9	10.8 ± 3.8	10.3 ± 4.0

The clinical value of the present investigation rests in the recognition of recognizing the potential danger zone for an invasive encroachment into the mandibular canal and its contents. The following tables chart the mm differences between the superior border of the mandibular canal to the inferior border of the mandible by category.

Table 4: ES minus ERT mm difference by category

mm	Cat 1	Cat 2	Cat 3	Cat 4	Cat 5	Cat 6	Cat 7	Totals
-1.0 to +2.0	7	4	19	6	2	0	2	40
+3.0	0	0	10	2	1	1	1	15
+4.0	0	0	9	5	0	1	0	15
+5.0	0	3	4	3	3	1	0	14
+6.0	0	0	2	2	0	1	1	6
+7.0	0	0	1	1	0	0	0	2
+8.0	0	0	0	0	1	1	0	2
+9.0	0	0	0	1	0	1	0	2
Totals	7	7	45	20	7	6	4	96

Table 5. ES minus IRT mm difference by category

mm	Cat 1	Cat 2	Cat 3	Cat 4	Cat 5	Cat 6	Cat 7	Totals
-1.0 to +2.0	6	3	19	6	2	0	1	37
+3.0	1	0	7	2	2	1	1	14
+4.0	0	1	10	6	0	2	1	20
+5.0	0	2	6	2	1	1	0	12
+6.0	0	1	2	3	1	0	1	8
+7.0	0	0	1	0	0	0	0	1
+8.0	0	0	0	0	0	1	0	1
+9.0	0	0	0	1	1	0	0	2
+10.0	0	0	0	0	0	1	0	1
Totals	7	7	45	20	7	5	4	96

Ignoring those measured differences that fall within 2 mm, a total of 56 of the total 96 scans demonstrated that the superior position of the mandibular canal as determined by the ES vs. the ERT was 3 mm or more in magnitude, and 12 of those were 6 mm or more. The numbers were not much different for ES vs. IRT. A total of 59 sites were 3 mm or more when ES was compared to IRT. These differences are graphically depicted in Fig 4.

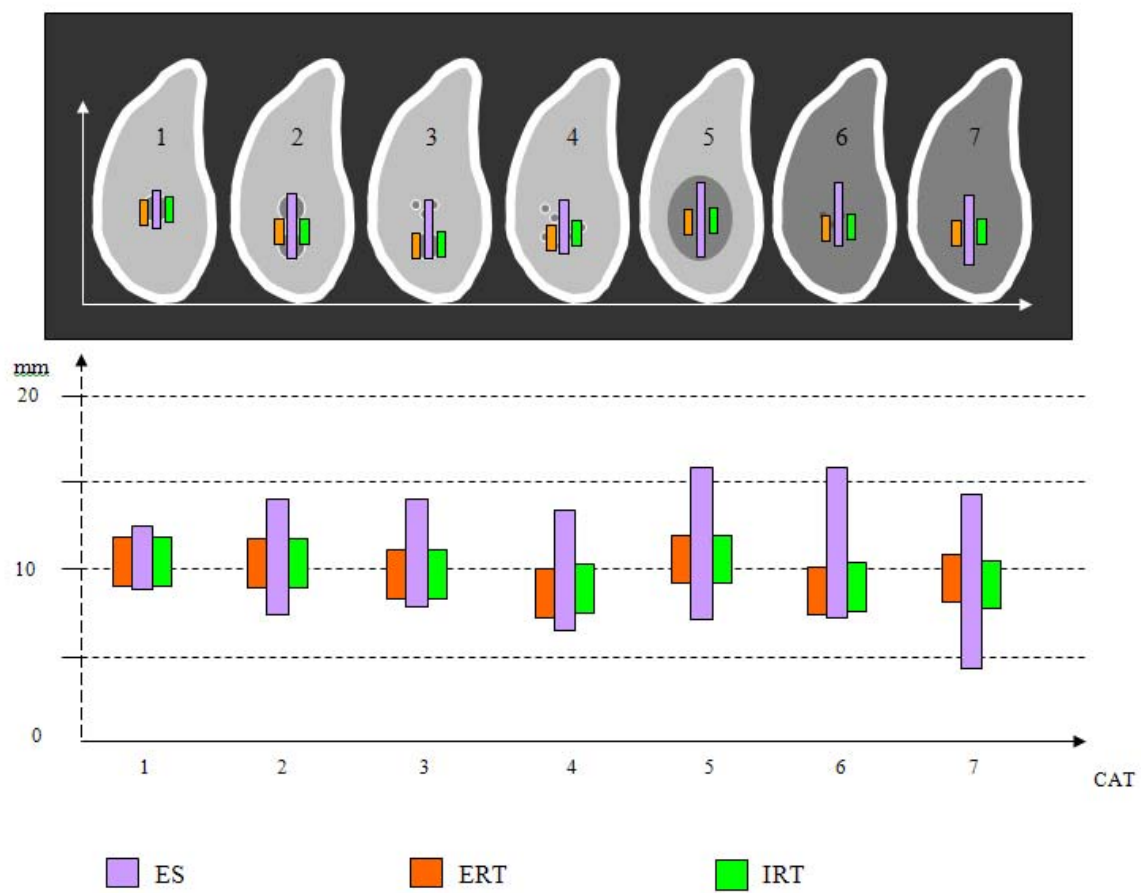


Figure 4: ES, IRT and ERT graphic representations of the suspected mandibular nerve

CHAPTER FOUR

DISCUSSION

The ES participating in this study has had 28 years involvement in an active dental implant surgical practice and has been using computed tomography radiographic device for 28 years of this practice period. The length of experience time does not, by itself, provide the training and expertise to read CBCT images and determine, beyond doubt, the identity and position of the mandibular nerve canal. Consequently there is no “gold standard” to use for comparisons. However, in light of the extensive literature describing a branching and varied anatomical path for the contents of the mandibular nerve and associated vascular components, it seems very likely that the rationale for pathway categories is justified. This experiment should be repeated using other experienced clinicians and possibly define a new “gold standard”.

On this same issue, the measurements proposed in the existing literature would promote the mandibular canal to resemble a single tubular form, exhibiting a vertical diameter of 2.5 to 3.0 mm dimension. This literature would provide support for, and may even be the basis for NMT technology.

The literature has proposed that the typical distance from the inferior border of the mandibular canal to the inferior border of the mandible would approximate 10 mm. The measurements from the present study for this distance was a mean of 7.1 to 8.0 mm with a Standard deviation of 1.8 to 2.2 mm.

The issue of the role of experience is addressed in this study as well. Admittedly the measurement of the vertical dimension of the mandibular canal was not part of the protocol for either the ERT or the IRT.

The real differences in the superior border of the mandibular canal location between the ES, ERT and the IRT were the result of the extensive variation in the mandibular nerve morphology as described in the categories. Mean mandibular canal measurement for Category 1 was only 4.1 mm. The majority of the sample would fall within Category 3 and 4, constituting 2/3 of the total number. Mean dimension for these categories would be 6.4 and 7.3 mm respectively, double the Simplant result.

As a consequence of this information, it appears from this research that little benefit is gleaned in extensive training for technicians utilizing the Simplant model. It would further appear that this automated model is most effective when the mandibular canal is confined in dimension, such as in Category 1.

CHAPTER FIVE

CONCLUSION

In view of the variability of the morphology of the coronal slides which is a direct representation of the variability in the anatomy of the mandible, it appears that implant surgeons should not rely on radiology technicians to mark the nerve. If an implant surgeon wants to use a nerve marking tool, they should be aware that the mandibular nerve is not always confined to one canal made of mineralized bone.

REFERENCES

1. Carter RB and Keen EN. The intramandibular course of the inferior alveolar nerve. *J Anat* 108: 433-440, 1971
2. Kieser JA, Paulin M and Law B. Intrabony course of the inferior alveolar nerve in the edentulous mandible. *Clin Anat*: 17: 107-111, 2004
3. Kieser J, Kieser D and Hauman T. The course and distribution of the inferior alveolar nerve in the edentulous mandible. *J Craniofac Surg* 16: 6-9, 2005
4. Kilic C, Kamburoglu K, Ozen T et al. The position of the mandibular canal and histologic feature of the inferior alveolar nerve. *Clin Anat* 23: 34-42, 2010
5. Kqiku L, Weiglein AH, Pertl C et al. Histology and intramandibular course of the inferior alveolar nerve. *Clin Oral Invest* 15: 1013-1016, 2011
6. Pogrel MA, Dorfman D and Fallah H. The anatomic structure of the inferior alveolar neurovascular bundle in the third molar region. *J Oral Maxillofac Surg* 67: 2452-2454, 2009
7. Wadu SG, Penhall B and Townsend GC. Morphological variability of the human inferior alveolar nerve. *Clin Anat* 10: 82-87, 1997
8. Gowgiel JM. The position and course of the mandibular canal. *J Oral Implant* 18: 383-385, 1992
9. Hwang K, Lee WJ, Song YB et al. Vulnerability of the inferior alveolar nerve and mental nerve during genioplasty: An anatomic study. *J of Craniofac Surg* 16: 10-14, 2005
10. Angelopoulos C, Thomas S, Hechler S et al. Comparison between digital panoramic radiography and cone-beam computed tomography for the identification of the mandibular canal as part of presurgical dental implant assessment. *J Oral Maxillofac Surg* 66: 2130-2135, 2008
11. Lofthag-Hansen S, Grondahl K and Ekestubbe A. Cone-beam CT for preoperative implant planning in the posterior mandible: Visibility of anatomic landmarks. *Clin Implant Dent and Related Res* 11: 246-255, 2009

12. Oliveira-Santos C, Capelozza ALA, Dezzoti MSG et al. Visibility of the mandibular canal on CBCT cross-sectional images. *J Appl Oral Sci* 19: 240-243, 2011