

9-2015

Morphological Changes in Alveolar Bone Following Orthodontic Space Closure

Ninette Hacopian

Follow this and additional works at: <http://scholarsrepository.llu.edu/etd>

 Part of the [Orthodontics and Orthodontology Commons](#)

Recommended Citation

Hacopian, Ninette, "Morphological Changes in Alveolar Bone Following Orthodontic Space Closure" (2015). *Loma Linda University Electronic Theses, Dissertations & Projects*. Paper 318.

This Thesis is brought to you for free and open access by TheScholarsRepository@LLU: Digital Archive of Research, Scholarship & Creative Works. It has been accepted for inclusion in Loma Linda University Electronic Theses, Dissertations & Projects by an authorized administrator of TheScholarsRepository@LLU: Digital Archive of Research, Scholarship & Creative Works. For more information, please contact scholarsrepository@llu.edu.

LOMA LINDA UNIVERSITY
School of Dentistry
in conjunction with the
Faculty of Graduate Studies

Morphological Changes in Alveolar Bone Following
Orthodontic Space Closure

by

Ninette Hacopian

A Dissertation submitted in partial satisfaction of
the requirements for the degree
Master of Science in Orthodontics and Dentofacial Orthopedics

September 2015

© 2015

Ninette Hacopian
All Rights Reserved

Each person whose signature appears below certifies that this thesis in his/her opinion is adequate, in scope and quality, as a thesis for the degree of Master of Science.

_____, Chairperson
Rodrigo Viecilli, Associate Professor of Orthodontics and Dentofacial Orthopedics

Joseph Caruso, Professor of Orthodontics and Dentofacial Orthopedics

Kitichai Rungcharassaeng, Professor of Orthodontics and Dentofacial Orthopedics

ACKNOWLEDGEMENTS

I would like to express my appreciation to the individuals who helped me complete this study. I am grateful to the Loma Linda University Department of Orthodontics and the members of my guidance committee. Thank you to Drs. Rodrigo Viecilli, Joseph Caruso and Kitichai Rungcharassaeng for their advice and comments.

CONTENT

Approval Page.....	iii
Acknowledgements.....	iv
List of Figures.....	vii
List of Tables.....	viii
List of Abbreviations.....	ix
Abstract.....	x
Chapter	
1. Review of the Literature.....	1
2. Morphological Changes in Alveolar Bone Following Orthodontic Space Closure	
Abstract.....	8
Introduction.....	10
Statement of Problem.....	10
Hypothesis.....	11
Materials and Methods.....	14
Patient selection.....	14
Inclusion Criteria.....	15
Extrusion Criteria.....	15
Data Collection.....	15
Segmentation.....	16
Volume Orientation.....	18
Voxel Based Registration.....	19
Measurements.....	20
Reference Points.....	20
Planes.....	21
Linear Measurements.....	22
Angular Measurements.....	24

Statistical Analysis.....	25
Results.....	26
Discussion.....	33
Conclusion	39
References.....	40
3. Discussion	
Extended Discussion.....	44
Study Improvements and Future Directions	46
References.....	47

FIGURES

Figures	Page
1. Anatomic structures of anterior cranial fossa region of the cranial base 3D surface models that were used for registration: A, superior view; B, inferior view.....	16
2. Segmentation of the anterior cranial base.....	17
3. Orientation of the occlusal plane parallel to the ground.....	18
4. Voxel based superimposition of T1 and T2 images on the anterior cranial base.....	19
5. Six points defining the change in the alveolar shape from T1 to T2 and the CRes measured at 33% of the root length.....	20
6. Point P'3: The point constructed from bisecting the angle formed by the palatal plane and palatal alveolar plane.....	21
7. Linear distance between the reference points and the long axis of the incisor.....	23
8. Angles between the buccal and palatal alveolar planes and the palatal plate and the angle between the long axis of the tooth and palatal plate.....	24

TABLES

Tables	Page
1. Mean values measured from CBCT image demonstrating the change in the position of the reference points between T1 and T2 in horizontal plane.....	27
2. Mean values measured from CBCT image demonstrating the change in the position of the reference points between T1 and T2 in vertical plane.	28
3. Mean values measured from CBCT image demonstrating the change in the linear distance of the reference points to the long axis of the incisor teeth between T1 and T2.....	29
4. Mean values measured from CBCT image demonstrating linear distance between the contralateral reference points between T1 and T2.....	29
5. Linear measurements demonstrating changes of the linear distance of CEJ to the buccal crestal bone and the thickness of the buccal alveolar bone at different levels between T1 and T2	30
6. Linear measurements demonstrating changes of the linear distance of CEJ to the lingual crestal bone and the thickness of the lingual alveolar bone at different levels between T1 and T2	30
7. Changes in the angular measurements between T1 and T2.....	31
8. Linear measurements demonstrating changes of the root length of central incisors and the position of the Center of Resistance of the teeth between T1 and T2.....	32

ABBREVIATIONS

CBCT	Cone Beam Computed Tomography
CEJ	Cementoenamel junction
CRes point	Center of resistance of the tooth which is at 33% of the root length measured from the CEJ of the central incisor
HRP	Horizontal reference plane
LA	Long axis of the upper central incisor
P1	The most coronal point on the labial alveolar crest
P'3	The most coronal point on the palatal alveolar crest
P2	The midpoint between point P1 and point P3
P'2	The midpoint between point P'1 and point P'3
P3	The deepest midline point on the pre-maxilla between anterior nasal spine and prosthion in the slice going through the long axis of the maxillary central incisors
P'3	The point constructed from bisecting the angle formed by the palatal plane and palatal alveolar plane
T1	Pre-orthodontic treatment
T2	Post-orthodontic treatment
VRP	Vertical reference plane

ABSTRACT OF THE THESIS

Morphological Changes in Alveolar Bone Following Orthodontic Space Closure

by

Ninette Hacopian

Master of Science, Graduate Program in Orthodontics
Loma Linda University, September 2015
Dr. Rodrigo Viecilli, Chairperson

Introduction: Changes occurring in anterior alveolar bone following orthodontic tooth movement are controversial. Some research has shown that orthodontic tooth movement results in the adaptation of cortical bone; others have shown that it results in dehiscence and fenestrations.

Purpose: The purpose of this study was to evaluate the alveolar bone changes around maxillary anterior teeth following orthodontic space closure.

Materials and Methods: Cone beam computed tomograms (CBCTs) of non-growing patients who received orthodontic treatment with bilateral maxillary premolar extraction were evaluated. Only patients with at least 5 degrees of changes in maxillary incisor (U1) to palatal plane angle were included in the study. Before (T1) and after (T2) orthodontic treatment CBCTs were reconstructed with the anterior cranial base segmented. The original T1 and T2 volumes and the segmented anterior cranial base volumes were superimposed using voxel based registration method. The superimposed sagittal images of right and left maxillary incisor were evaluated for alveolar bone changes. The distances from labial and palatal crest to CEJ were measured to evaluate vertical bone changes. Labial and palatal bone thicknesses at 3, 6, 9, 12 mm from CEJ as

well as the angles formed between palatal plane with labial and palatal alveolar plates were measured to evaluate the changes in the morphology of the maxillary alveolar process. A paired T-Test was used to compare the means of T1 and T2 measurements at the significance level of $\alpha = 0.05$.

Results: Twenty-six (7 male and 19 female) patients with a mean age of 22.1 years with a total of 49 maxillary central incisors were evaluated. The crestal alveolar bone showed statistically significant resorption both in the labial ($p = .038$) and palatal ($p < .001$) aspects. Significant losses in palatal bone thickness were observed at the 3, 6, and 9 mm from the CEJ ($p < .05$). Small gains in labial bone thickness were observed but they were not significant ($p > .05$).

Conclusion: Alveolar process modeling in the maxillary anterior teeth occurs in response to retraction during space closure. The most adversely affected area is the palatal crest, which might lead to periodontal consequences.

CHAPTER ONE

REVIEW OF THE LITERATURE

Tooth movement by orthodontic force application is characterized by modeling and modeling changes in dental and paradental tissue. Orthodontic tooth movement is a process whereby the application of a force induces bone resorption on the pressure side and bone apposition on the tension side. Combination of PDL modeling, and the localized apposition and resorption of alveolar bone enables the tooth to move.^{1,2,3}

Controversy exists whether the changes occurring in anterior alveolar bone during orthodontic tooth movement always follow the direction and extent of tooth movement. A basic axiom in orthodontics is ‘bone traces tooth movement,’⁴ which suggests that whenever orthodontic tooth movement occurs, the bone around the alveolar socket will remodel to the same extent. The association between vascular blood pressure in the PDL and hyalinization is one of the proposed theories of tooth movement in orthodontics.⁵ Later Viecilli et al described the role of P2X7 receptor in the transduction of orthodontic loads into bone adaptation and discussed that until then, the hyalination theory failed to consider the mechanotransduction events which lead to orthodontic tooth movement.⁶

Sometimes there may not be coherence with this rule, and an unfavorable bone response may occur after incisor retraction. For example, the increased bone due to a labial cortical plate is usually greater than the tooth displacement, leading to visible bone exostosis, labial bone protuberance, and an irregular ridge of bone. Labial bone protuberance usually causes esthetic problems, and alveoloplasty can be used to eliminate excess alveolar bone. Currently, the mechanisms leading to different alveolar bone responses are unclear; there is interest in determining the factors related to changes in

alveolar bone thickness during incisor retraction. Several studies have indicated a lag in bone modeling in response to tooth movement and reported that as the upper incisors are retracted, labial bone thickness at the crestal level and total alveolar bone thickness at the apical level significantly increase.³⁷

In a case reported by Mimura (2008), miniscrews were used for treatment of severe bimaxillary protrusion. The upper incisors were retracted 12 mm and intruded 5 mm over 20 months. During treatment an irregular ridge of bone developed labial to the upper incisors, bone was deposited in the incisive fossae and the apices of the upper incisors were resorbed. An alveoloplasty was carried out to recontour the labial bone and the incisive fossae. During extensive retraction, the teeth may contact structures not normally encountered during conventional orthodontic treatment.³⁸

In 1965 Baxter did a research studying the effect of orthodontic treatment on alveolar bone adjacent to the cemento-enamel junction in intraoral bitewing radiographs. His concluded that the relationship of the alveolar bone proper to the cemento-enamel junction at the mesial and distal of the teeth in intraoral bitewing can be measured to the nearest 0.5 mm. He observed a slight general decrease in the height of the alveolar bone proper of less than 0.5 mm following orthodontic treatment. He was not sure whether this change was due to treatment or a normal two year change in children ten to sixteen year of age. He did not find a significant difference in the change of the height of alveolar bone to the cemento-enamel junction between the non-extraction cases and cases in which first bicuspid had been extracted, or between first bicuspid extraction cases treated by edgewise appliance and Begg appliance. He found that moving teeth toward an extraction area had no specific effect upon the alveolar bone proper. Extrusion of teeth

during orthodontic treatment had no specific effect upon the alveolar bone proper, the bone appeared to follow the tooth, and a constant relationship between the height of the alveolar bone proper and the cemento-enamel junction was maintained. He concluded that in children in good health, the alveolar bone proper follows the tooth as it is moved mesiodistally or occlusally in orthodontic treatment, therefore maintaining a constant relationship between the alveolar bone and the cemento-enamel junction. It was also recorded in his study that this constant relationship is maintained both through bodily movement as well as tipping movement of teeth.³⁹

Changes in incisor inclination has been reported to affect points A and B. The findings of the study of Al-Abdawi et al demonstrated that 10 degrees change in the maxillary incisor inclination resulted in a statistically significant average change in point A of 0.4 mm in the horizontal plane. Each 10 degrees change in the mandibular incisor inclination resulted in a borderline statistically significant average change in point B of 0.3 mm in the horizontal plane. There were no significant changes in the vertical position of points A and B. The effects of incisal inclination changes, due to orthodontic treatment, are of no clinical relevance to the position of point A and B, even though they may be statistically significant. The validity of points A and B as skeletal landmarks generally holds true, and accounting for treatment changes is unnecessary.²⁷

In his research, Handelman hypothesized that as teeth are repositioned at their anatomic limits, the occurrence and severity of iatrogenic phenomena is enhanced. Thus, it is the occurrence of serious, unfavorable sequelae that may establish the limits of orthodontic treatment and define the borderline case as “orthodontic” or “surgical orthodontic”. He concluded that the width of the anterior alveolus combined with a

visualized treatment projection can be used in determining if the borderline patient is best treated via conventional orthodontics or a combined orthodontic-surgical program.⁴⁰

The validity of the postulate “bone traces tooth movement” was examined on 40 Angle CI II cases. It was hypothesized that a 1:1 cortical bone modeling/tooth movement ratio is preserved during maxillary incisor retraction. The sample was divided into retraction with tip (13 patients), retraction with torque (18 patients), and control (9 patients) groups. Two time point cephalograms were analyzed with two superimposition techniques, SN at S and a newly developed static tooth analysis, with the maxillary left central incisor serving as a reference object. In both retraction with tip and retraction with torque groups, the postulate bone traces tooth movement was not preserved and a bone modeling/tooth movement ratio of 1:2 and 1:2.35 was obtained, respectively. In retraction with tip movement, the apical one third of the root tipped labially reducing the superior area of labial maxillary area by 19%. However, due to the compensating effect of the retraction movement, no apex approximation to the labial cortical plate occurred (eliminating the hazard of root resorption, dehiscence, or fenestration). In retraction with torque movement, the increase in both superior (28%) and inferior (65%) labial maxillary areas was indicative for the hazard of root approximation to the palatal cortical bone. It is recommended to use the 1:2 bone modeling/tooth movement ratio as a guideline to determine the biocompatible range of orthodontic tooth movements. Furthermore, a judicious interplay between the two modes of retraction can prevent major biologic impairment associated with the ratio and can extend the orthodontic range of treatment.⁴¹

Many studies have shown that cone-beam computed tomography (CBCT) can be used as a tool to qualitatively evaluate hard-tissue changes in the alveolar bone plates in

three dimensions, as the technique has a one-to-one image-to-reality ratio and the measurements are not affected by changes in the orientation of the skull.^{7,42}

Exploring the alveolar architecture, the bone support of each tooth, before starting treatment is important for safe planning for each patient. During orthodontic treatment, for example, projection and retraction of the anterior teeth are common. However, the thickness of the alveolar bone on the anterior teeth is a factor that should be considered and measured before and during treatment because the amount of bone in the region can limit tooth movement and the maintenance of periodontal health. So to study the alveolar bone at the start of treatment to minimize the deleterious effects of orthodontic therapy, Ferreira et al aimed to detect the absence of bone coverage in the anterior region through axial and sagittal reconstructions by CBCT. They found that in the sagittal and axial reconstructions, regions without bone coverage were diagnosed in 91.03% of cases as “cortex not seen” or “minimum thickness, fine, without marrow bone.” Cone-beam computed tomography can help in the diagnosis of lack of bone coverage on the buccal surfaces of anterior teeth. There was no difference in the performance of the axial and sagittal reconstructions. Although in the middle third, the sagittal section was shown to be more reliable than the axial section.⁴³

The study of Yodthonget et al demonstrated that a rapid rate of incisor retraction increased bone thickness at the labial crestal level. The bone-modeling process may not be able to keep up with rapid tooth movement; however, their results indicated that total alveolar bone thickness was maintained. It can be interpreted from this observation that the rate of resorption on the labial aspect is relatively slower than the rate of apposition on the lingual aspect (secondary bone modeling), which may lead to bone prominence.

Labial bone thickness at the crestal level and total alveolar bone thickness at the apical level significantly increased during upper incisor retraction. The factors related to changes in alveolar bone thickness during incisor retraction were the rate of tooth movement, the degree of inclination change, and the extent of intrusion of the upper incisors.⁴⁴

It has been suggested that the amount of anterior alveolar bone might increase during orthodontic treatment involving lingual positioning of protrusive teeth.³³ Other findings regarding the degree of labial alveolar bone change do not support this claim. Apparently the apposition process in the labial inner cortical plate is somewhat slower than is the resorption process in the labial outer cortical plate. It is clear that either some bone apposition or some plastic deformation of the cortical plates also takes place at the compression site.⁴⁶

CHAPTER TWO
MORPHOLOGICAL CHANGES IN ALVEOLAR BONE FOLLOWING
ORTHODONTIC SPACE CLOSURE

by

Ninette Hacopian

Master of Science, Graduate Program in Orthodontics and Dentofacial Orthopedics

Loma Linda University, September 2015

Dr. Rodrigo Viecilli, Chairperson

Abstract

Introduction: Changes occurring in anterior alveolar bone following orthodontic tooth movement are controversial. Some research has shown that orthodontic tooth movement results in the adaptation of cortical bone; others have shown that it results in dehiscence and fenestrations.

Purpose: The purpose of this study was to evaluate the alveolar bone changes around maxillary anterior teeth following orthodontic space closure.

Materials and Methods: Cone beam computed tomograms (CBCTs) of non-growing patients who received orthodontic treatment with bilateral maxillary premolar extraction were evaluated. Only patients with at least 5 degrees of changes in maxillary incisor (U1) to palatal plane angle were included in the study. Before (T1) and after (T2) orthodontic treatment CBCTs were reconstructed with the anterior cranial base segmented. The original T1 and T2 volumes and the segmented anterior cranial base volumes were superimposed using voxel based registration method. The superimposed sagittal images of right and left maxillary incisor were evaluated for alveolar bone changes. The distances from labial and palatal crest to CEJ were measured to evaluate vertical bone changes. Labial and palatal bone thicknesses at 3, 6, 9, 12 mm from CEJ as well as the angles formed between palatal plane with labial and palatal alveolar plates were measured to evaluate the changes in the morphology of the maxillary alveolar process. A paired T-Test was used to compare the means of T1 and T2 measurements at the significance level of $\alpha = 0.05$.

Results: Twenty-six (7 male and 19 female) patients with a mean age of 22.1 years with a total of 49 maxillary central incisors were evaluated. The crestal alveolar

bone showed statistically significant resorption both in the labial ($p = .038$) and palatal ($p < .001$) aspects. Significant losses in palatal bone thickness were observed at the 3, 6, and 9 mm from the CEJ ($p < .05$). Small gains in labial bone thickness were observed but they were not significant ($p > .05$).

Conclusion: Alveolar process modeling in the maxillary anterior teeth occurs in response to retraction during space closure. The most adversely affected area is the palatal crest, which might lead to periodontal consequences.

Introduction

Statement of the Problem

The alveolar bone is traditionally and practically considered the anatomical limitation of orthodontic tooth movement.^{1,2,3} Controversy exists on whether the changes occurring in anterior alveolar bone during orthodontic tooth movement always follow the direction and extent of tooth movement. A basic axiom in orthodontics is ‘bone traces tooth movement,’⁴ which suggests that whenever orthodontic tooth movement occurs, the bone around the alveolar socket will model to the same extent. The association between vascular blood pressure in the PDL and hyalinization is one of the proposed theories of tooth movement in orthodontics.⁵ Later Viecilli et al described the role of P2X7 receptor in the transduction of orthodontic loads into bone adaptation and discussed that until then, the hyalinization theory failed to consider the mechanotransduction events which lead to orthodontic tooth movement.⁶

The adaptation of the alveolar bone is clinically significant on a regular basis when it comes to treatment planning. The amount of correction required for crowding, as well as well as for other orthodontic mechanics that require anterior tooth movement, largely depends on the position of the incisors within the alveolar bone. Multiple studies in the past have evaluated the effects of tooth movement on the alveolar bone using cadavers and patients that have needed procedures involving periodontal flaps.⁷ While this information was useful, it was based on two-dimensional representation of a three dimensional structure. CBCT now allows for a more accurate measurement of the three dimensional changes that occur to the alveolar bone due to orthodontic tooth movement.^{8,9,10}

The purpose of this study is to evaluate the changes of the alveolar bone surrounding maxillary anterior teeth following space closure. This study will compare the alveolar bone changes acquired before (T1) and after (T2) orthodontic space closure.

Hypothesis

The central null hypothesis is that there is no change in the morphology of the maxillary alveolar bone following orthodontic tooth movement, which can be divided in sub-hypotheses as follows:

1. The distance between point P1 and HRP does not change from T1 to T2.
2. The distance between point P1 and VRP does not change from T1 to T2.
3. The distance between point P'1 and HRP does not change from T1 to T2.
4. The distance between point P'1 and VRP does not change from T1 to T2.
5. The distance between point P2 and HRP does not change from T1 to T2.
6. The distance between point P2 and VRP does not change from T1 to T2.
7. The distance between point P'2 and HRP does not change from T1 to T2.
8. The distance between point P'2 and VRP does not change from T1 to T2.
9. The distance between point P3 and HRP does not change from T1 to T2.
10. The distance between point P3 and VRP does not change from T1 to T2.
11. The distance between point P'3 and HRP does not change from T1 to T2.
12. The distance between point P'3 and VRP does not change from T1 to T2.
13. The distance between point P1 and long axis of the tooth does not change from T1 to T2.
14. The distance between point P'1 and long axis of the tooth does not change from T1 to T2.

15. The distance between point P2 and long axis of the tooth does not change from T1 to T2.
16. The distance between point P'2 and long axis of the tooth does not change from T1 to T2.
17. The distance between point P3 and long axis of the tooth does not change from T1 to T2.
18. The distance between point P'3 and long axis of the tooth does not change from T1 to T2.
19. The distance between points P1 and P'1 does not change from T1 to T2.
20. The distance between points P2 and P'2 does not change from T1 to T2.
21. The distance between points P3 and P'3 does not change from T1 to T2.
22. The angle formed between the labial alveolar plane and the palatal plane does not change from T1 to T2.
23. The angle formed between the palatal alveolar plane and the palatal plane does not change from T1 to T2.
24. The angle formed between the long axis of the incisor teeth and the palatal plane does not change from T1 to T2.
25. The distance between the CRes of the tooth and the HRP does not change from T1 to T2.
26. The distance between the CRes of the tooth and the VRP does not change from T1 to T2.
27. The root length of the incisor does not change from T1 to T2.

28. The distance between CEJ and the buccal alveolar crest does not change from T1 to T2.
29. The distance between CEJ and the lingual alveolar crest does not change from T1 to T2.
30. The thickness of the buccal bone at 3 mm of root length does not change from T1 to T2.
31. The thickness of the palatal bone at 3 mm of root length does not change from T1 to T2.
32. The thickness of the buccal bone at 6 mm of root length does not change from T1 to T2.
33. The thickness of the palatal bone at 6 mm of root length does not change from T1 to T2.
34. The thickness of the buccal bone at 9 mm of root length does not change from T1 to T2.
35. The thickness of the palatal bone at 9 mm of root length does not change from T1 to T2.
36. The thickness of the buccal bone at 12 mm of root length does not change from T1 to T2.
37. The thickness of the palatal bone at 12 mm of root length does not change from T1 to T2.

Materials and Methods

Patient Selection

The Study used 3D CBCT radiographs taken at the beginning of Orthodontic treatment (T1) and at the completion of Orthodontic Treatment (T2). To keep measurements consistent, only one experimenter performed the reconstruction and assessment. Cases were selected using the inclusion/exclusion criteria described below:

Inclusion Criteria

1. Full treatment case with T1 and T2 records
2. Patients who have completed most of their growth, age 15 for females and age 19 for males
3. Extraction patients
4. A change in incisor angulation of ≥ 5 degrees or 3mm of retraction in relation to A-Po

Extrusion Criteria

1. Missing anterior teeth
2. Phase one cases
3. Severely rotated anterior teeth
4. Maxillary Surgery

Data Collection

The charts of non-growing patients treated at Loma Linda University with NewTom 3G images were reviewed and the following data recorded:

1. Chart Number
2. Sex (male or female)
3. Age at beginning of treatment

Segmentation of the Anterior Cranial Base

In the radiographic protocol, the data from each CBCT scan were saved as digital imaging and communications in medicine (DICOM) files. Model construction and cranial base registration were performed using methods described by Nguyen et al,¹¹ and Cevidanes et al.¹² Three-dimensional surface models of the anatomic region of interest were constructed from the T1 and T2 images of each patient using ITK-SNAP¹³ (open-source software; <http://www.itksnap.org>) (Figure 1). The initial and final CBCT images were registered on anterior cranial fossa structures, specifically the endocranial surfaces of the cribriform plate region of the ethmoid bone and the internal surface of the frontal bone (Figure 2). These regions were chosen because of their early completion of growth.

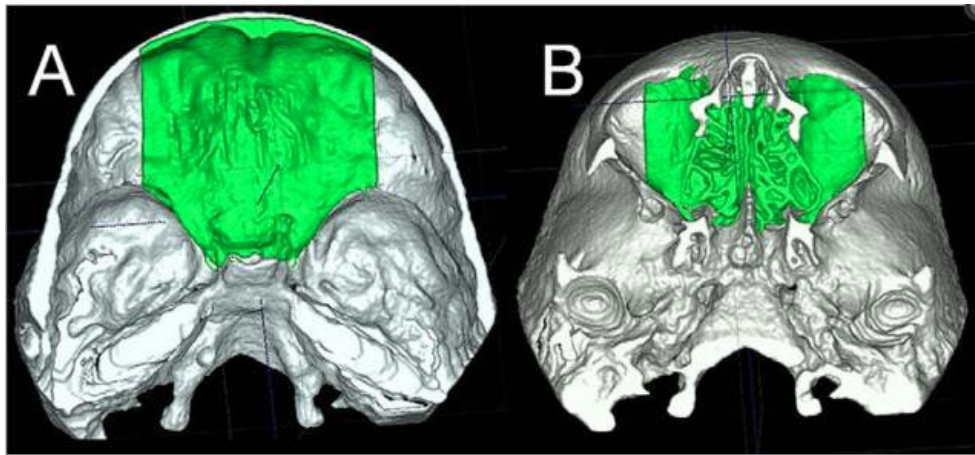


Figure 1: Anatomic structures of anterior cranial fossa region of the cranial base 3D surface models that were used for registration: A, superior view; B, inferior view.

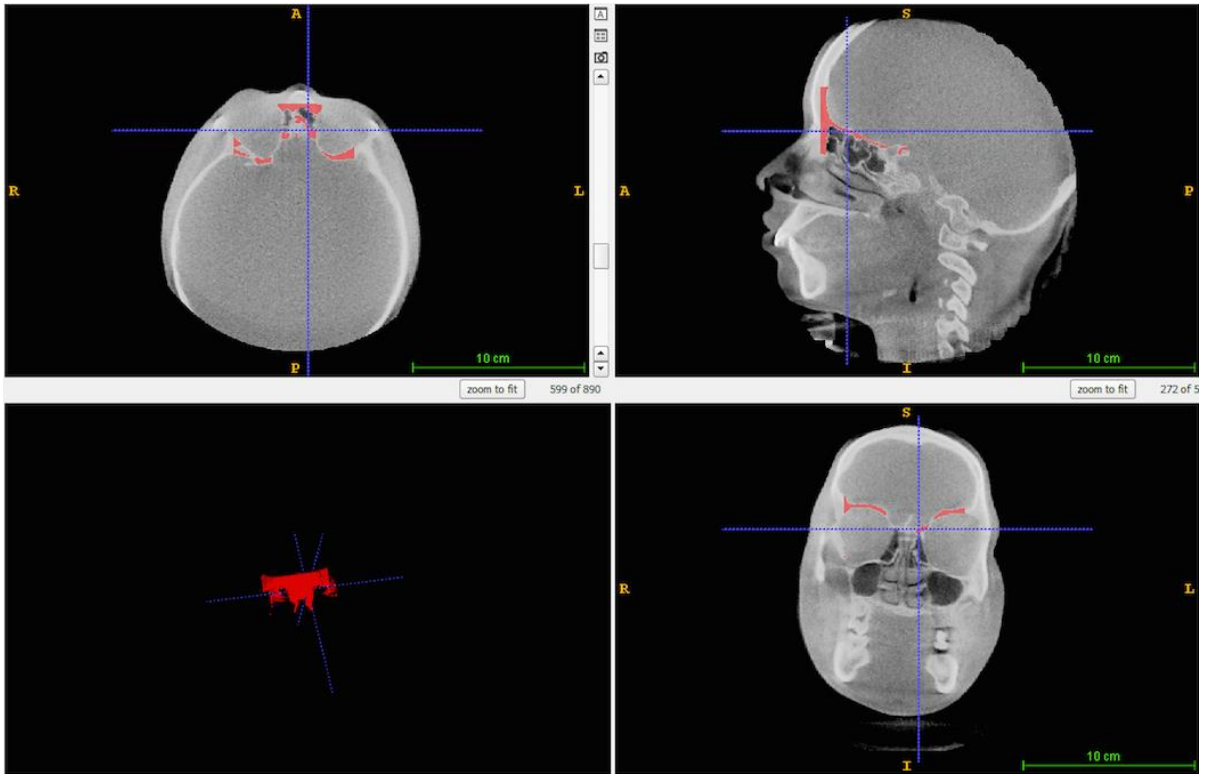


Figure 2: Segmentation of the anterior cranial base.

Volume Orientation

The T1, T2 DICOM images as well as the T1 and T2 segmentation images were imported into 3D SLICER¹⁴ (open-source software; <http://www.slicer.org>) and each volume was oriented so that the occlusal plane would be parallel to the horizontal plane (Figure 3).

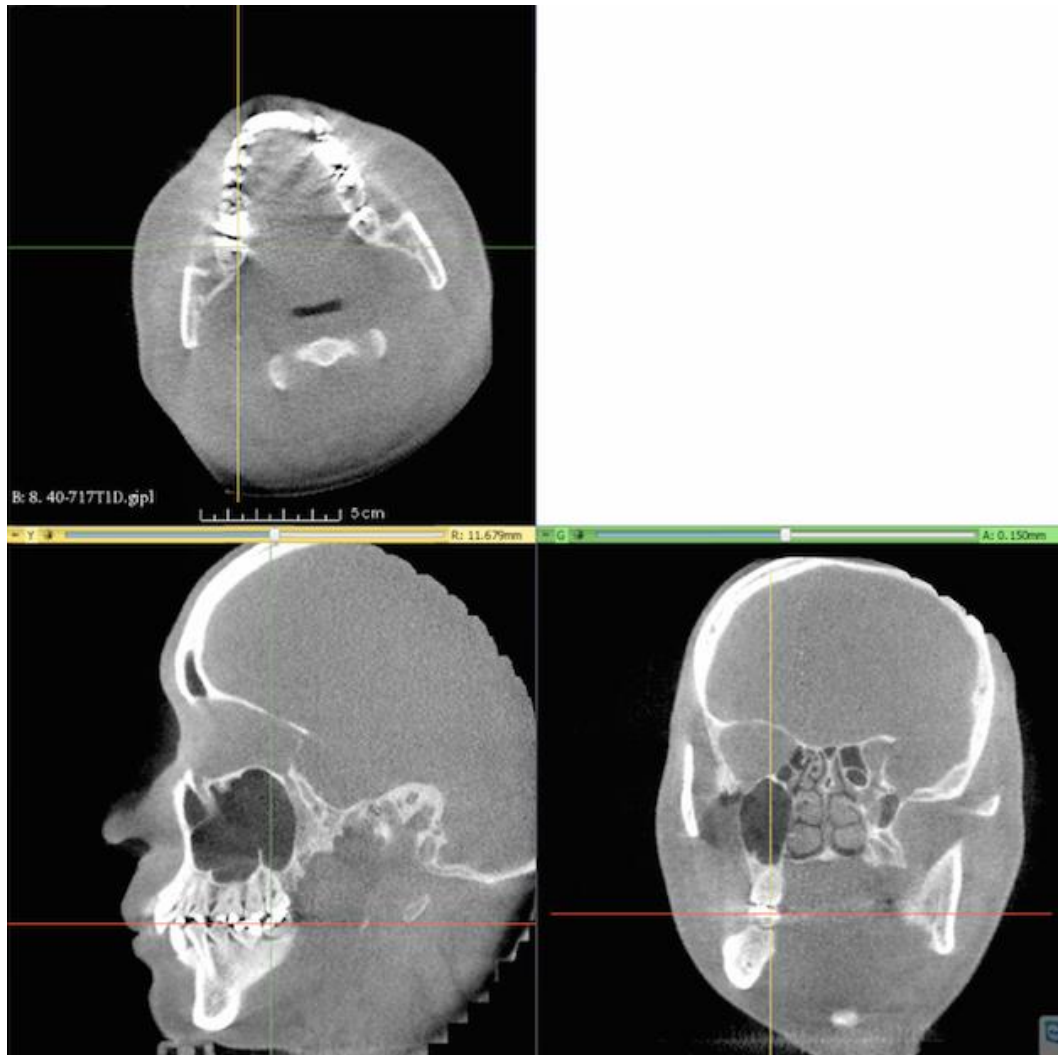


Figure 3: Orientation of the occlusal plane parallel to the ground.

Voxel Based Registration

After orienting the T1 image, the T1 and T2 images were first superimposed manually. After manual superimposition, a fully automated voxel-based registration method was performed with 3D SLICER¹⁴ (open-source software; <http://www.slicer.org>). This software computes the rigid registration (translation and rotation) that aligns the T1 and T2 gray-level CBCT data sets optimally with subvoxel accuracy at the anterior cranial base (Figure 4).

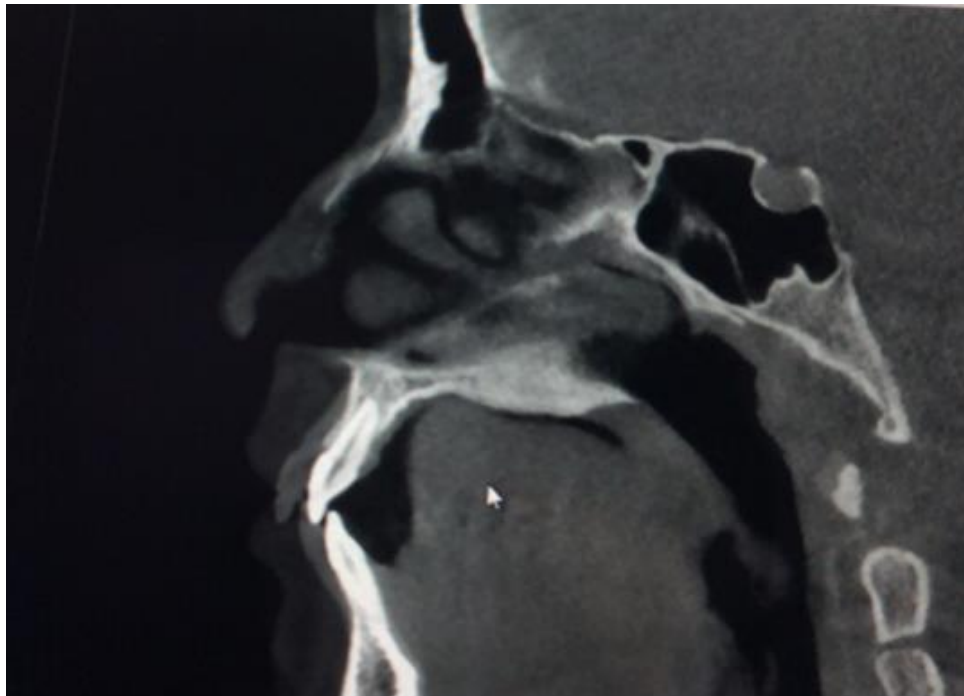


Figure 4: Voxel based registration of T1 and T2 images on the anterior cranial base.

Measurements

Seven anatomic or constructed landmarks and three angles were used to measure the change in the maxillary alveolar process morphology.

Reference Points (Figure 4):

1. Point P1: The most coronal point on the labial alveolar crest.
2. Point P'1: The most coronal point on the palatal alveolar crest.

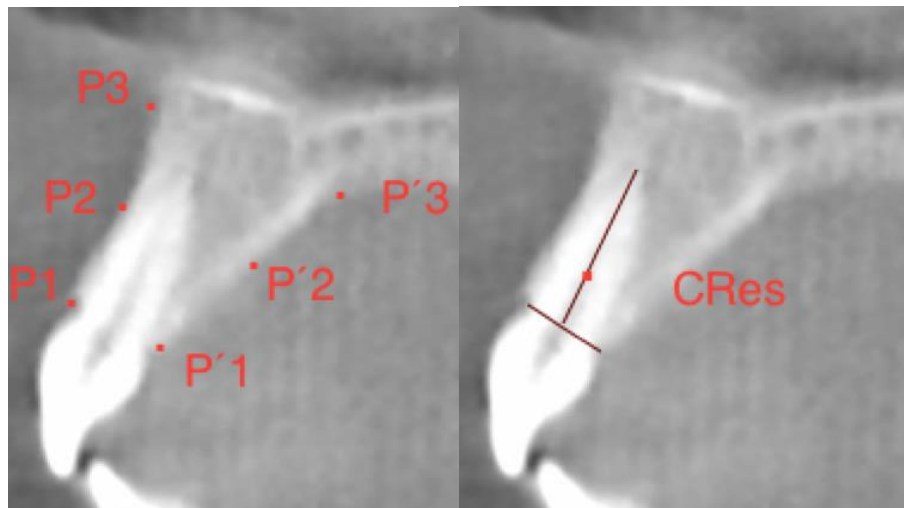


Figure 5. Six points defining the change in the alveolar shape from T1 to T2 and the CRes measured at 33% of the root length.

3. Point P3: The deepest midline point on the pre-maxilla between anterior nasal spine and prosthion in the slice going through the long axis of the maxillary central incisors.
2. Point P'3: The point constructed from bisecting the angle formed by the palatal plane and palatal alveolar plane (Figure 4)
5. Point P2: The midpoint between point P1 and point P3.
6. Point P'2: The midpoint between point P'1 and point P'3.

7. CR point: Center of resistance of the tooth which is at 33% of the root length measured from the CEJ of the central incisor.




Figure 6. Point P'3: The point constructed from bisecting the angle formed by the palatal plane and palatal alveolar plane.

Planes

1. Labial alveolar plane: This plane is constructed by extending the line from P2 to P3.
2. Palatal alveolar plane: This plane is constructed by extending the line from P'2 to P'3.
3. Long axis of the incisor: The line drawn through the root canal of the central incisor.

To measure the changes in the morphology of the alveolar process the following measurements will be taken: (Figures 8)

Linear Measurements

1. The distance between point P1 and HRP.
2. The distance between point P1 and VRP.
3. The distance between point P'1 and HRP.
4. The distance between point P'1 and VRP.
5. The distance between point P2 and HRP.
6. The distance between point P2 and VRP.
7. The distance between point P'2 and HRP.
8. The distance between point P'2 and VRP.
9. The distance between point P3 and HRP.
10. The distance between point P3 and VRP.
11. The distance between point P'3 and HRP.
12. The distance between point P'3 and VRP.
13. The distance between point P1 and long axis of the tooth.
14. The distance between point P'1 and long axis of the tooth.
15. The distance between point P2 and long axis of the tooth.
16. The distance between point P'2 and long axis of the tooth.
17. The distance between point P3 and long axis of the tooth.
18. The distance between point P'3 and long axis of the tooth.
19. The distance between points P3 and P'3.
20. The distance between points P2 and P'2.
21. The distance between points P3 and P'3.
22. The distance between the CRes of the tooth and the HRP.

23. The distance between the CRes of the tooth and the VRP.
24. The root length of the incisor does not change from T1 to T2.
25. The distance between CEJ and the buccal alveolar crest.
26. The distance between CEJ and the lingual alveolar crest.
27. The thickness of the buccal bone at 3 mm of root length does.
28. The thickness of the palatal bone at 3 mm of root length does.
29. The thickness of the buccal bone at 6 mm of root length.
30. The thickness of the palatal bone at 6 mm of root length.
31. The thickness of the buccal bone at 9 mm of root length.
32. The thickness of the palatal bone at 9 mm of root length.
33. The thickness of the buccal bone at 12 mm of root length.
34. The thickness of the palatal bone at 12 mm of root length.

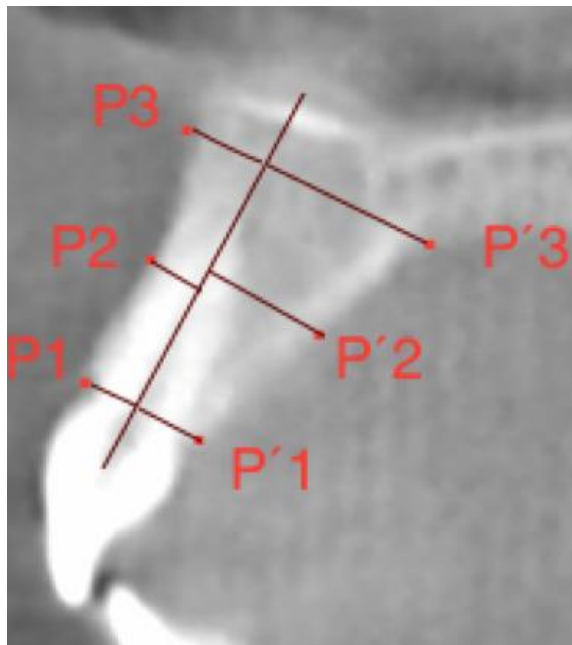


Figure 7: Linear distance between the reference points and the long axis of the incisor.

Angular Measurements (Figure 9)

1. The angle formed between the labial alveolar plane and the palatal plane.
2. The angle formed between the palatal alveolar plane and the palatal plane.
3. The angle formed between the long axis of the incisor teeth and the palatal.




Figure 8. Angles between the buccal and palatal alveolar planes and the palatal plate and the angle between the long axis of the tooth and palatal plate.

Statistical Analysis

Statistical analyses were performed using IBM SPSS Statistics (Version 22; IBM Corporation 1989, 2013.). Descriptive statistics were given as mean \pm standard deviation if the data were normally distributed or median with interquartile range if the data were not normally distributed, for the T1 and T2 measurements. Wilcoxon Signed Rank Test was used to compare the means of pre and post measurements. The consistency of the measurements were assessed for agreements using intra-class correlation coefficient.

Alpha was set at 0.05 significance level.

30% of the measurements were used to determine reliability of the examiner. 95% confidence intervals will be built around the measure of intra-class correlation.

Results

Data were obtained from 26 non-growing patients at the Orthodontic Clinic at Loma Linda University. Of the twenty six patients that met the inclusion criteria, 7 were male and 19 were female. The mean age of the patients 22.1 years. Forty-nine teeth were evaluated in this study.

The CBCT of the patients were segmented at the anterior cranial base and the pre-treatment (T1) and post-treatment (T2) images were superimposed on the anterior cranial base using the voxel based technique. A number of linear and angular measurements were used to study the morphological changes of the alveolar bone following orthodontic space closure.

Table 1 to 8 shows the mean and standard deviations of all measured parameters at T1 and T2 for the entire sample. A related samples Wilcoxon Signed Rank test at a significance of $\alpha= 0.05$ was used for the statistical analysis of the change of the linear and angular measurements between T1 and T2.

Table 1. Mean values measured from CBCT image demonstrating the change in the position of the reference points between T1 and T2 in horizontal plane.

Parameter	T1 (Mean \pm SD)	T2 (Mean \pm SD)	T2-T1 (Mean \pm SD)	P-value
$\Delta P1_x$ (mm)	15.69 \pm 5.10	15.05 \pm 5.13	-0.63 \pm 0.44	0.000*
$\Delta P2_x$ (mm)	13.87 \pm 5.10	13.52 \pm 5.03	-0.35 \pm 0.38	0.000*
$\Delta P3_x$ (mm)	12.62 \pm 4.99	12.63 \pm 4.94	0.016 \pm 0.31	0.619
$\Delta P'1_x$ (mm)	13.82 \pm 5.12	12.68 \pm 5.06	-1.14 \pm 0.59	0.000*
$\Delta P'2_x$ (mm)	10.93 \pm 5.09	10.70 \pm 5.13	-0.22 \pm 0.94	0.000*
$\Delta P'3_x$ (mm)	7.83 \pm 4.95	7.94 \pm 4.96	0.10 \pm 0.39	0.075

*Statistically Significant

The results of the CBCT measurements are shown in Tables 1 to 8. There was a significant difference between the mean T1 and T2 in a number of measurements. Table 1 shows the mean values measured from CBCT image demonstrating the change in the position of the reference points between T1 and T2 in horizontal plane. The mean measurements representing the horizontal position of the point M3 didn't show significant changes from T1 to T2. The mean changes in the horizontal position of point P2 and P'2 were highly significant ($P < .001$). The mean changes in horizontal positions of points P1 and P'1 were also highly significant from T1 to T2 ($P \leq .001$).

Table 2. Mean values measured from CBCT image demonstrating the change in the position of the reference points between T1 and T2 in vertical plane.

Parameter	T1 (Mean \pm SD)	T2 (Mean \pm SD)	T2-T1 (Mean \pm SD)	P-value
ΔP_{1y} (mm)	5.43 \pm 2.89	5.15 \pm 2.95	-0.28 \pm 0.78	0.001*
ΔP_{2y} (mm)	3.14 \pm 2.82	3.03 \pm 2.90	-0.11 \pm 0.68	0.047*
ΔP_{3y} (mm)	0.82 \pm 2.88	0.81 \pm 2.80	0.00 \pm 0.36	0.533
$\Delta P'_{1y}$ (mm)	6.74 \pm 2.78	6.12 \pm 2.83	-0.62 \pm 0.94	0.000*
$\Delta P'_{2y}$ (mm)	4.45 \pm 2.65	3.96 \pm 2.67	-0.49 \pm 0.65	0.000*
$\Delta P'_{3y}$ (mm)	2.59 \pm 2.77	2.52 \pm 2.76	-0.06 \pm 0.51	0.832

*Statistically Significant

Table 2 shows the mean values measured from CBCT image demonstrating the change in the position of the reference points between T1 and T2 in vertical plane. The mean measures representing the vertical position of the points P3 and P'3 didn't show significant changes from T1 to T2. The mean changes in the vertical positions of point P'2 were highly significant ($P < .001$). The mean change in the vertical position of point P2 was also significant but to a lesser degree ($P < .05$). The mean changes in the vertical positions of points P1 and P'1 were all highly significant from T1 to T2 ($P \leq .001$).

Table 3. Mean values measured from CBCT image demonstrating the change in the linear distance of the reference points to the long axis of the incisor teeth between T1 and T2.

Parameter	T1 (Mean \pm SD)	T2 (Mean \pm SD)	T2-T1(Mean \pm SD)	P-value
P1-LA (mm)	3.35 \pm 0.41	3.43 \pm 0.42	0.07 \pm 0.54	0.363
P2-LA (mm)	2.86 \pm 0.70	2.88 \pm 1.42	0.02 \pm 1.41	0.842
P3-LA (mm)	3.89 \pm 1.45	3.31 \pm 2.61	-0.58 \pm 2.75	0.078
P'1-LA (mm)	4.15 \pm 0.40	3.94 \pm 0.61	-0.20 \pm 0.63	0.079
P'2-LA (mm)	6.58 \pm 1.11	8.00 \pm 1.61	1.42 \pm 1.89	0.798
P'3-LA (mm)	10.30 \pm 1.92	11.00 \pm 2.72	0.70 \pm 2.78	0.053

*Statistically Significant

The mean changes in the linear distance of the reference points to the long axis of the incisor teeth between T1 and T2 are shown in Table 3. None of the measurement demonstrated statistically significant changes from T1 to T2.

Table 4. Mean values measured from CBCT image demonstrating linear distance between the labial and lingual reference points between T1 and T2.

Parameter	T1 (Mean \pm SD)	T2 (Mean \pm SD)	T2-T1(Mean \pm SD)	P-value
P1-P'1 (mm)	7.51 \pm 0.48	7.75 \pm 0.60	0.23 \pm 0.57	0.003*
P2-P'2 (mm)	9.80 \pm 1.34	9.59 \pm 1.50	-0.20 \pm 1.19	0.212
P3- P'3 (mm)	18.17 \pm 2.44	14.51 \pm 2.43	-3.65 \pm 2.86	0.109

*Statistically Significant

The mean changes in the linear distance between the labial and lingual reference points between T1 and T2 are shown in Table 4. The distance between the buccal and lingual crestal bone of the incisors demonstrate statistically significant changes ($P < .05$).

Table 5. Linear measurements demonstrating changes of the linear distance of CEJ to the buccal crestal bone and the thickness of the buccal alveolar bone at different levels between T1 and T2.

Parameter	T1 (Mean \pm SD)	T2 (Mean \pm SD)	T2-T1(Mean \pm SD)	P-value
CEJ-bC (mm)	1.79 \pm 0.92	2.05 \pm 0.96	0.25 \pm 0.92	0.038*
BB-3mm (mm)	1.05 \pm 0.50	1.15 \pm 0.73	0.09 \pm 0.61	0.185
BB-6mm (mm)	1.19 \pm 0.47	1.36 \pm 0.73	0.17 \pm 0.76	0.061
BB-9mm (mm)	1.29 \pm 0.74	1.47 \pm 0.72	0.18 \pm 0.90	0.095
BB-12mm (mm)	1.90 \pm 1.22	2.31 \pm 1.22	0.41 \pm 1.59	0.003*

*Statistically Significant

Table 6. Linear measurements demonstrating changes of the linear distance of CEJ to the lingual crestal bone and the thickness of the lingual alveolar bone at different levels between T1 and T2.

Parameter	T1 (Mean \pm SD)	T2 (Mean \pm SD)	T2-T1(Mean \pm SD)	P-value
CEJ-IC (mm)	1.81 \pm 0.91	3.10 \pm 1.68	1.28 \pm 1.83	0.000*
LB-3mm (mm)	1.39 \pm 0.78	0.58 \pm 0.70	-0.81 \pm 0.78	0.000*
LB-6mm (mm)	2.46 \pm 0.80	1.59 \pm 1.03	-0.87 \pm 1.13	0.000*
LB-9mm (mm)	3.65 \pm 1.16	2.83 \pm 1.31	-0.81 \pm 1.6	0.002*
LB-12mm (mm)	5.36 \pm 1.32	5.82 \pm 1.73	0.45 \pm 2.14	0.088

*Statistically Significant

The linear measurements demonstrating changes of the linear distance of CEJ to the buccal and lingual crestal bone and the thickness of the buccal and lingual alveolar bone at different levels between T1 and T2 are shown in tables 5 and 6. The mean distance between CEJ and the crestal bone showed significant change from T1 to T2 in both the labial ($P < .05$) and the lingual ($P < .001$), though the mean increase in the distance was far more significant in the lingual side compared to the buccal side. Regarding the mean changes in the thickness of the alveolar bone, the measurement at 3 mm and 6mm of the long axis from CEJ in the lingual showed highly significant changes from T1 to T2 ($P < .001$). The mean changes at 9 mm in the lingual and 12 mm in the buccal were also significant ($P < .005$).

Table 7. Changes in the angular measurements between T1 and T2.

Parameter	T1 (Mean \pm SD)	T2(Mean \pm SD)	T2-T1(Mean \pm SD)	P-value
L-PP (°)	108.93 \pm 6.76	105.47 \pm 12.37	3.46 \pm 10.05	0.008*
P-PP (°)	132.47 \pm 7.66	133.89 \pm 8.34	1.41 \pm 4.46	0.025*
LA-PP (°)	116.51 \pm 7.02	106.11 \pm 6.99	10.40 \pm 6.00	0.000*

*Statistically Significant

Table 7 shows that after retraction of the incisor teeth, the mean angles between the labial and the palatal alveolar plates and the palatal plane showed statistically significant changes which was more remarkable in the labial ($P < .01$) than the palatal side ($P < .05$). The mean angle between the long axis of the tooth and the palatal plane showed highly significant change from T1 to T2 ($P < .001$).

Table 8. Linear measurements demonstrating changes of the root length of central incisors and the position of the Center of Resistance of the teeth between T1 and T2.

Parameter	T1 (Mean \pm SD)	T2 (Mean \pm SD)	T2-T1(Mean \pm SD)	P-value
RL (mm)	13.25 \pm 1.41	11.87 \pm 1.38	1.38 \pm 0.77	0.000*
Δ CRes _x (mm)	14.25 \pm 5.06	13.60 \pm 5.09	0.64 \pm 0.59	0.000*
Δ CRes _y (mm)	5.13 \pm 2.77	5.05 \pm 2.76	0.08 \pm 0.80	0.715

*Statistically Significant

Table 8 shows the mean amount of root resorption after retraction of upper incisors was highly significant ($P < .001$). Of the mean changes in the position of the center of resistance of the incisors, only the mean change in the horizontal position was significant ($P < .001$). The CRes of the incisor teeth did not show significant vertical changes from T1 to T2.

To determine the intra-rater variability 15 samples were randomly selected and measured. 95% confidence intervals was built around the measure of intra-class correlation. The results showed a correlation coefficient of 0.9-1.0 indicating an almost perfect level of agreement according to Landis and Koch interpretation.¹⁵

Discussion

In orthodontics, mechanical forces are transferred to the teeth, leading to mechanical loading of the root surrounding periodontal ligament (PDL). Histological evaluations present a tension side associated with bone formation and a compression side coupled with bone resorption. Beside this, modeling of the extracellular matrix is indispensable to generating orthodontic tooth movement.¹⁵ Modeling of the alveolar bone during orthodontic treatment has been considered a useful method for tissue regeneration when there is insufficient alveolar bone.¹⁷

Two concepts are suggested for orthodontic tooth movement in terms of alveolar bone modeling. The first concept which is called “with the bone” implies that if the alveolar bone is modeled with coordination of resorption and apposition, tooth movement and bone modeling occur at a 1:1 ratio, thus the tooth remains in the alveolar housing. However, if the ratio between tooth movement and bone modeling is not 1:1 and the balance between resorption and apposition of the alveolar bone is not established during tooth movement, the tooth may move out of the alveolar housing, which is referred to as “through-the-bone” type of tooth movement.¹⁸

The concept of bone modeling-to-tooth movement (B/T) has been an issue of investigation in the orthodontics. In cases of non-orthodontic tooth movement, during eruption of the dentition, simultaneous alveolar ridge augmentation occurs as teeth emerge from the alveolar process.¹⁹ It has also been shown that in the presence of inflammatory periodontal disease, tooth movement can actually cause more bone resorption. In this process tooth movement exceeds bony apposition.²⁰ The 1:1 B/T ratio

is probably not preserved in pathologic conditions such as overeruption and tooth submergence,^{21,22,23} where the ratio is less in the former and greater in the latter.

In regard to changes in the position of point A following maxillary incisor movement, Subtenly et al suggest that labial root torque of the incisors promote development of point A, indicating that point A advancement may be an important adjunct to face mask therapy.²⁴ In another study Labial root torque in combination with tying the arch wire forward produced a greater rate of advancement of Downs' point A when compared with normal growth. This caused an increase in skeletal convexity, while normal growth straightened the profile.²⁵ Erverdi et al demonstrated that the axial inclination of the maxillary central teeth is one of the factors influencing the location of point A. In this study, the relationship between the axial inclination of the upper central incisor and the location of point A was evaluated. Four criteria that define the location of the maxillary central teeth were used: I (incisal point), Ap (apical point), R (rotation point), and I-SN (angle between I and SN plane). A significant positive correlation was found between the locations of points A and R. They also calculated a regression equation for this relationship.²⁶ The findings of the present study demonstrate that the horizontal and vertical positions of the basal points (A, A') did not change following retraction of maxillary incisors, confirms that tooth movement does not affect the basal skeletal areas. According to Al-Abdwani each 10 degrees change in the maxillary incisor inclination results in a statistically significant average change in point A of 0.4 mm in the horizontal plane. He concludes that the effects of incisal inclination changes, due to orthodontic treatment, are of no clinical relevance to the position of point A, even though they may be statistically significant. The validity of points A and B as skeletal landmarks

generally holds true, and accounting for treatment changes is unnecessary.²⁷ In our study which was an evaluation of CBCT slices, point P3 was defined as the deepest midline point on the pre-maxilla between anterior nasal spine and prosthion in the slice going through the long axis of the maxillary central incisors. In the present study none of the horizontal or vertical measurements of the maxillary base (P3 and P'3) showed any statistically significant changes before and after maxillary incisor retraction. This can be due to fact that the average tooth movement type was controlled tipping, so the apex and likewise point P3 did not change much.

On the other hand, all the parameters measuring changes in the position of alveolar process (P1, P'1, P2, P'2) showed statistically significant changes both in the horizontal and vertical planes of space, implying that the position of the alveolar bone has changed following tooth movement. Horizontally the parameters have followed the direction of tooth movement. On measuring the midpoint, the displacement of point P2 was greater than point P'2. On the other hand the lingual displacement of point P1' was greater than point P1, which may imply less lingual displacement of the middle portion of the tooth compared to the cervical portion that is more lingual tipping of the teeth. It has been demonstrated that in the sagittal dimension the B/T ratio varies in the posterior vs anterior segments. In the posterior dental segment, a 1:1 B/T ratio can be maintained if tooth movement is restrained between the two cortical plates.¹² It has been demonstrated that during orthodontic treatment, buccolingual movement exceeding the alveolar bone may result in bony dehiscence at the crest area and cause gingival recession.²⁸ Dehiscence and fenestration of the buccal cortical plate suggests that buccal movement of roots surpass bone modeling in the transverse direction.²⁹

Vertically, all the measured parameters showed apical displacement at T2. This implies resorption of the crestal alveolar bone following retraction of the incisor teeth. Previous studies have demonstrated that bone increase in vertical dimension is less than dental displacement which may be favorable during forced eruption³⁰ and unfavorable when extrusion of impacted teeth.³¹

Of the parameters measuring the labiolingual thickness of the bone, only the P1-P'1 showed significant change which was a 0.23 mm increase. This finding may imply greater amount of tooth displacement in the cervical region, bone formation in the area following tooth movement or it may be a result of compensatory strain-mediated modeling due to initial bending of the crestal alveolar bone.

The increase in the distance between the CEJ to the crestal bone was significant at both labial and lingual sides. The change in the lingual side was highly significant (1.28 mm, $P=0.000$), and was five times greater compared to the labial side (0.25 mm, $P < .005$).

The findings of the present study showed no significant changes in the buccal bone thickness at 3,6, and 9 mms which may imply the alveolar bone followed the incisor teeth movement in the lingual direction and hence the overall thickness of the alveolar bone remained constant. On the other hand the measurements of the lingual alveolar bone thickness at the 3, 6, and 9 mm were highly significant and showed decrease in all instances, implying less following of the alveolar bone at lingual. The measurement BB-12mm showed a significant increase of 0.41 mm. Though the amount of increase in the lingual side was more than the labial side (0.45 mm), but it was not statistically significant. Interpreting the change in the thickness of the alveolar bone at 12 mm may be

misleading since in some instances, due to the root resorption which happened as a result of tooth movement, the distance of the CEJ to the apex was less than 12 mm.

All three angular measurements showed significant changes from T1 to T2. The central incisors showed an average decrease of the inclination of 10 degrees. Changes in the angulation of the labial and palatal alveolar plates implies a change in the inclination of the alveolar process lingually. The mean reduction was about 3.5 degrees in the labial alveolar plate and only 1.5 degrees in the palatal alveolar plate indicating a greater amount of alveolar bending in the labial vs palatal plate.

According to Meikle et al producing clinically significant skeletal modeling can be exercised to avoid destruction of the palatal alveolar cortex during overjet reduction, even where extractions are an essential part of the treatment program. This will be more efficient during growth years when facial skeleton responds to mechanical deformation more readily. For this reason, it may be beneficial to start treatment before all the permanent teeth have erupted.³²

Excessive retraction of the anterior teeth may result in iatrogenic sequelae such as root resorption, alveolar bone loss, dehiscence, fenestration, and gingival recession.^{33,34,35,36} The root resorption that occurred after the retraction of maxillary incisors was in average 1.38 mm which was highly significant ($P < .001$). Patients with dentoalveolar protrusion usually have thin and elongated anterior alveoli before treatment, pushing the tooth against the thin cortical bone may cause root resorption and/or an alveolar bone defect. Excessive root movement as a result of using bracket prescriptions with excessive tooth torque may cause greater root movement and increased risk of root resorption.¹⁸

Evaluating the change in the CRes of the incisors before and after treatment in the present study demonstrated a mean 0.64 mm distal movement which was highly significant ($P < .001$) and a non-significant change of 0.08 mm apically. The finding implies no significant extrusion or intrusion occurred during retraction of incisors.

Conclusion

The results of the present study indicate that basal bone does not change following retraction of maxillary incisors. Overall, alveolar bone following incisor tooth movement is greater in labial than lingual side. The same thing applies to angular changes, the change in the angulation of the labial alveolar plate was about 2.5 times more than the palatal alveolar plate. The crestal bone resorption was highly significant in the lingual side and was 5 times greater than that of labial side. Bending of the alveolar process was demonstrated both through increased distance between the labial and lingual crestal reference points and also by significant angular changes of the labial and palatal plates.

References

1. Reitan K. Tissue behavior during orthodontic tooth movement. *Am J Orthodontics* 1960;46:881-900.
2. Krishnan V, Davidovitch Z. Cellular, molecular, and tissue-level reactions to orthodontic force. *Am J Orthod Dentofacial Orthop* 2006;129:469e.1-460e.32.
3. Henneman S, Von den Hoff JW, Maltha JC. Mechanobiology of tooth movement. *Eur J Orthod* 30;2008:299–306.
4. Reitan K. Effects of force magnitude and direction of tooth movement on different alveolar bone types. *Angle Orthod* 1964;34:244-55.
5. Reitan KR. Principles and biomechanical reactions. In: Graber TM, Vanarsdall RL, editors. *Orthodontics: current principles and techniques*. St Louis: Mosby; 1994. p. 88-174.
6. Viecilli RF, Katona TR, Chen J, Hartsfield JK Jr, Roberts WE. Orthodontic mechanotransduction and the role of the P2X7 receptor. *Am J Orthod Dentofacial Orthop* 2009;135:694.e1-694e.16
7. Fuhrmann RA, Wehrbein H, Langen HJ, Diedrich PR. Assessment of the dentate alveolar process with high resolution computed tomography. *Dentomaxillofac Radiol* 1995;24:50-4.
8. Ludlow JB, Davies-Ludlow LE, Brooks SL. Dosimetry of two extraoral direct digital imaging devices: NewTom cone beam CT and Orthophos Plus DS panoramic unit. *Dentomaxillofac Radiol*. 2003;32:229-34.
9. Molen AD. Considerations in the use of cone-beam computed tomography for buccal bone measurements. *Am J Orthod Dentofacial Orthop* 2010;137:130-5.
10. Silva MA, Wolfe U, Heinicke F, Bumann A, Visser H, Hirsch E. Cone-beam computed tomography for routine orthodontic treatment planning: a radiation dose evaluation. *Am J Orthod Dentofacial Orthop* 2008;133:640.e1-5.
11. Nguyen T, Cevidanes L, Cornelis MA, Heymann G, de Paula LK, De Clerck H. Three-dimensional assessment of maxillary changes associated with bone anchored maxillary protraction. *Am J Orthod Dentofacial Orthop*. 2011;140:790–8.
12. Cevidanes LH, Heymann G, Cornelis MA, De Clerck HJ, Tulloch JF. Superimposition of 3-dimensional cone-beam computed tomography models of growing patients. *Am J Orthod Dentofacial Orthop*. 2009;136:94–9.

13. Paul A. Yushkevich, Joseph Piven, Heather Cody Hazlett, Rachel Gimpel Smith, Sean Ho, James C. Gee, and Guido Gerig. User-guided 3D active contour segmentation of anatomical structures: Significantly improved efficiency and reliability. *Neuroimage* 2006 Jul 1;31:1116-28.
14. Fedorov A., Beichel R., Kalpathy-Cramer J., Finet J., Fillion-Robin J-C., Pujol S., Bauer C., Jennings D., Fennessy F., Sonka M., Buatti J., Aylward S.R., Miller J.V., Pieper S., Kikinis R. 3D Slicer as an Image Computing Platform for the Quantitative Imaging Network. *Magn Reson Imaging*. 2012;30:1323-41.
15. Nettelhoff L, Grimm S, Jacobs C, Walter C, Pabst AM, Goldschmitt J, Wehrbein H. Influence of mechanical compression on human periodontal ligament fibroblasts and osteoblasts. *Clin Oral Investig*. 2015 Aug 6. [Epub ahead of print]
16. Ogodscu A., Sinescu C., Ogodescu E., Popescu M., Stratul S., Talpos S., Rusu D. Biology of the alveolar bone: Orthodontic tissue regeneration (OTR). *Advances in Biology, Bioengineering and Environment* 1989;9:240-244.
17. Ahn HW, Moon SC, Baek SH. Morphometric evaluation of changes in the alveolar bone and roots of the maxillary anterior teeth before and after en masse retraction using cone-beam computed tomography. *Angle Orthod*. 2013;83:212-21.
18. Marks SC Jr, Cahill DR, Wise GE. The cytology of the dental follicle and adjacent alveolar bone during tooth eruption in the dog. *Am J Anat*. 1983;168:277-89.
19. Gazit E, Lieberman M. Occlusal and orthodontic considerations in the periodontally involved dentition. *Angle Orthod*. 1980;50:346-9.
20. Kurol J, Thilander B. Infraocclusion of primary molars and the effect on occlusal development, a longitudinal study. *Eur J Orthod*. 1984;6:277-93.
21. Becker A1, Karnei-R'em RM. The effects of infraocclusion: Part 1. Tilting of the adjacent teeth and local space loss. *Am J Orthod Dentofacial Orthop*. 1992;102:256-64.
22. Becker A1, Karnei-R'em RM. The effects of infraocclusion: Part 2. The type of movement of the adjacent teeth and their vertical development. *Am J Orthod Dentofacial Orthop*. 1992;102:302-9.
23. Subtelny JD. Oral respiration: facial maldevelopment and corrective dentofacial orthopedics. *Angle Orthod* 1980;50:147-64.
24. Goldin B. Labial root torque: Effect on the maxilla and incisor root apex. *Am J Orthod Dentofacial Orthop* 1989;95:208-19.

25. Evernedi N. A cephalometric study of changes in point A under the influence of upper incisor inclinations. *J Nihon Univ Sch Dent.* 1991;33:160-5.
26. Al-Abdwani R, Moles DR, Noar JH. Change of Incisor Inclination Effects on Points A and B. *Angle Orthod.* 2009;79:462–467.
27. Yared KF, Zenobio EG, Pacheco W. Periodontal status of mandibular central incisors after orthodontic proclination in adults. *Am J Orthod Dentofacial Orthop.* 2006;130:6.e1-8.
28. Vardimon AD, Graber TM, Voss LR, Lenke J. Determinants controlling iatrogenic external root resorption and repair during and after palatal expansion. *Angle Orthod.* 1991;61;113-24.
29. Berglundh T, Marinello CP, Lindhe J, Thilander B, Liljenberg B. Periodontal tissue reactions to orthodontic extrusion. An experimental study in the dog. *J Clin Periodontol.* 1991;18:330-6.
30. Wang WG, Wang WN. Forced eruption: an alternative to extraction or periodontal surgery. *J Clin Orthod.* 1992;26:146-9.
31. Meikle MC. The dentomaxillary complex and overjet correction in Class II, division 1 malocclusion: objectives of skeletal and alveolar remodeling. *Am J Orthod* 1966;52:353-70.
32. Sarikaya S, Haydar B, Ciger S, Ariyurek M. Changes in alveolar bone thickness due to retraction of anterior teeth. *Am J Orthod Dentofacial Orthop.* 2002;122:15–26.
33. Ten Hoeve A, Mulie RM. The effect of antero-postero incisor repositioning on the palatal cortex as studied with laminag- raphy. *J Clin Orthod.* 1976;10:804–822.
34. Wainwright WM. Faciolingual tooth movement: its influence on the root and cortical plate. *Am J Orthod.* 1973;64:278–302.
35. Wehrbein H, Fuhrmann RAW, Diedrich PR. Periodontal conditions after facial root tipping and palatal root torque of incisors. *Am J Orthod Dentofacial Orthop.* 1994;106:455–462.
36. Lin J, Yeh C, Liou E, Bowman S. Treatment of skeletal-origin gummy smile with miniscrew anchorage. *J Clin Orthod.* 2008;5:285–296.
37. Mimura H. Treatment of severe bimaxillary protrusion with miniscrew anchorage: treatment and complication. *Aust Ortho J.* 2008;24:156–163.
38. Baxter DH. The effect of orthodontic treatment on alveolar bone adjacent to the cetnento-enamel junction. *Angle Orthod:*1967;37:35-47.

39. Handelman CS. The anterior alveolus: its importance in limiting orthodontic treatment and its influence on the occurrence of iatrogenic sequelae. *Angle Orthod.* 1996;66(2):95-109.
40. Vardimon A, Oren E, Ben-Bassat Y. Cortical bone remodeling/tooth movement ratio during maxillary incisor retraction with tip vs torque movements. *Am J Orthod Dentofacial Orthop* 1998; 114:520-5.
41. Lagravère MO, Carey J, Toogood RW, Major PW. Three-dimensional accuracy of measurements made with software on cone-beam computed tomography images. *Am J Orthod Dentofacial Orthop* 2008;134:112-16.
42. Ferreira PP, Torres M, Campos PS, Vogel CJ, de Araújo TM, Rebello IM. Evaluation of buccal bone coverage in the anterior region by cone-beam computed tomography. *Am J Orthod Dentofacial Orthop* 2013;144:698-704.
43. Yodthong N, Charoemratrote C, Leethanakul C. Factors related to alveolar bone thickness during upper incisor retraction. *Angle Orthod* 2013;83:394–401.
44. Bimstein E, Crevoisier RA, King DL. Changes in the morphology of the buccal alveolar bone of protruded permanent mandibular incisors secondary to orthodontic alignment. *Am J Orthod Dentofacial Orthop* 1990;97:427-30.

CHAPTER THREE

DISCUSSION

Extended Discussion

To obtain desired alveolar bone response while retracing the incisors, fundamental knowledge should be taken into consideration. Bone quantity should be considered as a limitation, and the magnitude and direction of the force should be controlled. Concentration of stress and deformation, esp at the labial and lingual crestal region may lead to local alveolar bone loss to modify its structure in order to decrease alveolar strains.⁴⁷

Previous studies reported that recovery of the dense cortical plate would be difficult when the root penetrates the cortical plate. Longitudinal studies are required to investigate the capacity of alveolar bone modeling and will help determine whether repair of alveolar bone takes place after incisor retraction and during the retention period.^{33, 35}

Cone-beam computed tomography has become a popular modality in diagnosing orthodontic problems and evaluation of treatment outcomes. Conventional two-dimensional (2D) lateral cephalograms have several limitations in terms of investigating the changes in the alveolar bone and roots, especially in the anterior region, as a result of the midsagittal projection. The advent of cone-beam computed tomography (CBCT) has made it possible to qualitatively and quantitatively evaluate the height and thickness of the alveolar bone and the length and thickness of the root.^{18, 40}

Previous studies have investigated the accuracy of linear measurements from lateral cephalometric images derived from cone-beam computed tomography.⁴⁸ Spatial resolution and its contributing factors should be considered during the design or

interpretation of CBCT studies. The 2 most common voxel sizes used in orthodontics—0.3 and 0.4 mm—provide lower spatial resolution than smaller voxel sizes and should be used with caution if the goal is to assess small variations in bone thickness. Voxels are not the same size in all three dimensions. The voxel resolution of the DICOM files used in this study ranged from 0.36 x 0.36 x 0.30 to 0.42 x 0.42 x 0.40. A smaller voxel size would be more appropriate for these studies and would also decrease the influence of partial volume averaging.⁴⁹

Bone turnover following orthodontic tooth movement is an important factor to consider when measuring bony structures, since osteoclastic activity causes a decrease in bone density.⁵⁰ According to the results of the previous studies, properly conducted studies should include a time point at least 1 year post-treatment to allow the bone to remature after bone turnover. Buccal bone measurements made during active treatment have limited value.⁴⁹

Study improvements and future directions

As with any study there are always areas that could have been improved. First, increasing the sample size would help increase the power and clinical significance of the study. Second, including the lower incisors in the study would help demonstrate the differences in the behavior of maxillary vs mandibular alveolar process following retraction of the incisors. The third was that most of the T1 CBCT images were taken on the Newtom 3g machine that had a lower resolution when compared to the Newtom 5g. The higher the resolution, the more accurate the measurements would be.

For future research it would be helpful to study how the B/T ratio changes in anteroposterior, vertical, and transverse directions and also to investigate whether both cortical and cancellous bone respond to the tooth movement to the same extent. Also it would be helpful to perform the same research in growing patients to find out how the alveolar processes respond to tooth movement in growing patients.

A measurement of pure bony change may be possible in future with high resolution CBCT images through accurately separating tooth and the alveolar process. Also, valuable information would be obtained by looking at patients one year after cessation of orthodontic treatment to evaluate the bone shape after the bone has gained its density.

REFERENCES

1. Reitan K. Tissue behavior during orthodontic tooth movement. *Am J Orthodontics* 1960;46:881-900.
2. Krishnan V, Davidovitch Z. Cellular, molecular, and tissue-level reactions to orthodontic force. *Am J Orthod Dentofacial Orthop* 2006;129:469e.1-460e.32.
3. Henneman S, Von den Hoff JW, Maltha JC. Mechanobiology of tooth movement. *Eur J Orthod* 30;2008:299–306.
4. Reitan K. Effects of force magnitude and direction of tooth movement on different alveolar bone types. *Angle Orthod* 1964;34:244-55.
5. Reitan KR. Principles and biomechanical reactions. In: Graber TM, Vanarsdall RL, editors. *Orthodontics: current principles and techniques*. St Louis: Mosby; 1994. p. 88-174.
6. Vecilli RF, Katona TR, Chen J, Hartsfield JK Jr, Roberts WE. Orthodontic mechanotransduction and the role of the P2X7 receptor. *Am J Orthod Dentofacial Orthop* 2009;135:694.e1-694e.16
7. Fuhrmann RA, Wehrbein H, Langen HJ, Diedrich PR. Assessment of the dentate alveolar process with high resolution computed tomography. *Dentomaxillofac Radiol* 1995;24:50-4.
8. Ludlow JB, Davies-Ludlow LE, Brooks SL. Dosimetry of two extraoral direct digital imaging devices: NewTom cone beam CT and Orthophos Plus DS panoramic unit. *Dentomaxillofac Radiol*. 2003;32:229-34.
9. Molen AD. Considerations in the use of cone-beam computed tomography for buccal bone measurements. *Am J Orthod Dentofacial Orthop* 2010;137:130-5.
10. Silva MA, Wolfe U, Heinicke F, Bumann A, Visser H, Hirsch E. Cone-beam computed tomography for routine orthodontic treatment planning: a radiation dose evaluation. *Am J Orthod Dentofacial Orthop* 2008;133:640.e1-5.
11. Nguyen T, Cevitanes L, Cornelis MA, Heymann G, de Paula LK, De Clerck H. Three-dimensional assessment of maxillary changes associated with bone anchored maxillary protraction. *Am J Orthod Dentofacial Orthop*. 2011;140:790–8.
12. Cevitanes LH, Heymann G, Cornelis MA, De Clerck HJ, Tulloch JF. Superimposition of 3-dimensional cone-beam computed tomography models of growing patients. *Am J Orthod Dentofacial Orthop*. 2009;136:94–9.

13. Paul A. Yushkevich, Joseph Piven, Heather Cody Hazlett, Rachel Gimpel Smith, Sean Ho, James C. Gee, and Guido Gerig. User-guided 3D active contour segmentation of anatomical structures: Significantly improved efficiency and reliability. *Neuroimage* 2006 Jul 1;31:1116-28.
14. Fedorov A., Beichel R., Kalpathy-Cramer J., Finet J., Fillion-Robin J-C., Pujol S., Bauer C., Jennings D., Fennessy F., Sonka M., Buatti J., Aylward S.R., Miller J.V., Pieper S., Kikinis R. 3D Slicer as an Image Computing Platform for the Quantitative Imaging Network. *Magn Reson Imaging*. 2012;30:1323-41.
15. Landis JR, Koch GC. The measurement of observer agreement for categorical data. *Biometrics*. 1977;33:159-174.
16. Nettelhoff L, Grimm S, Jacobs C, Walter C, Pabst AM, Goldschmitt J, Wehrbein H. Influence of mechanical compression on human periodontal ligament fibroblasts and osteoblasts. *Clin Oral Investig*. 2015 Aug 6. [Epub ahead of print]
17. Ogodscu A., Sinescu C., Ogodescu E., Popescu M., Stratul S., Talpos S., Rusu D. Biology of the alveolar bone: Orthodontic tissue regeneration (OTR). *Advances in Biology, Bioengineering and Environment* 1989;9:240-244.
18. Ahn HW, Moon SC, Baek SH. Morphometric evaluation of changes in the alveolar bone and roots of the maxillary anterior teeth before and after en masse retraction using cone-beam computed tomography. *Angle Orthod*. 2013;83:212-21.
19. Marks SC Jr, Cahill DR, Wise GE. The cytology of the dental follicle and adjacent alveolar bone during tooth eruption in the dog. *Am J Anat*. 1983;168:277-89.
20. Gazit E, Lieberman M. Occlusal and orthodontic considerations in the periodontally involved dentition. *Angle Orthod*. 1980;50:346-9.
21. Kurol J, Thilander B. Infraocclusion of primary molars and the effect on occlusal development, a longitudinal study. *Eur J Orthod*. 1984;6:277-93.
22. Becker A1, Karnei-R'em RM. The effects of infraocclusion: Part 1. Tilting of the adjacent teeth and local space loss. *Am J Orthod Dentofacial Orthop*. 1992;102:256-64.
23. Becker A1, Karnei-R'em RM. The effects of infraocclusion: Part 2. The type of movement of the adjacent teeth and their vertical development. *Am J Orthod Dentofacial Orthop*. 1992;102:302-9.
24. Subtelny JD. Oral respiration: facial maldevelopment and corrective dentofacial orthopedics. *Angle Orthod* 1980;50:147-64.

25. Goldin B. Labial root torque: Effect on the maxilla and incisor root apex. *Am J Orthod Dentofacial Orthop* 1989;95:208-19.
26. Evernedi N. A cephalometric study of changes in point A under the influence of upper incisor inclinations. *J Nihon Univ Sch Dent*. 1991;33:160-5.
27. Al-Abdwani R, Moles DR, Noar JH. Change of Incisor Inclination Effects on Points A and B. *Angle Orthod*. 2009;79:462–467.
28. Yared KF, Zenobio EG, Pacheco W. Periodontal status of mandibular central incisors after orthodontic proclination in adults. *Am J Orthod Dentofacial Orthop*. 2006;130:6.e1-8.
29. Vardimon AD, Graber TM, Voss LR, Lenke J. Determinants controlling iatrogenic external root resorption and repair during and after palatal expansion. *Angle Orthod*. 1991;61:113-24.
30. Berglundh T, Marinello CP, Lindhe J, Thilander B, Liljenberg B. Periodontal tissue reactions to orthodontic extrusion. An experimental study in the dog. *J Clin Periodontol*. 1991;18:330-6.
31. Wang WG, Wang WN. Forced eruption: an alternative to extraction or periodontal surgery. *J Clin Orthod*. 1992;26:146-9.
32. Meikle MC. The dentomaxillary complex and overjet correction in Class II, division 1 malocclusion: objectives of skeletal and alveolar remodeling. *Am J Orthod* 1966;52:353-70.
33. Sarikaya S, Haydar B, Ciger S, Ariyurek M. Changes in alveolar bone thickness due to retraction of anterior teeth. *Am J Orthod Dentofacial Orthop*. 2002;122:15–26.
34. Ten Hoeve A, Mulie RM. The effect of antero-postero incisor repositioning on the palatal cortex as studied with laminag- raphy. *J Clin Orthod*. 1976;10:804–822.
35. Wainwright WM. Faciolingual tooth movement: its influence on the root and cortical plate. *Am J Orthod*. 1973;64:278–302.
36. Wehrbein H, Fuhrmann RAW, Diedrich PR. Periodontal conditions after facial root tipping and palatal root torque of incisors. *Am J Orthod Dentofacial Orthop*. 1994;106:455–462.
37. Lin J, Yeh C, Liou E, Bowman S. Treatment of skeletal-origin gummy smile with miniscrew anchorage. *J Clin Orthod*. 2008;5:285–296.
38. Mimura H. Treatment of severe bimaxillary protrusion with miniscrew anchorage: treatment and complication. *Aust Ortho J*. 2008;24:156–163.

39. Baxter DH. The effect of orthodontic treatment on alveolar bone adjacent to the cemento-enamel junction. *Angle Orthod*:1967;37:35-47.
40. Handelman CS. The anterior alveolus: its importance in limiting orthodontic treatment and its influence on the occurrence of iatrogenic sequelae. *Angle Orthod*. 1996;66(2):95-109.
41. Vardimon A, Oren E, Ben-Bassat Y. Cortical bone remodeling/tooth movement ratio during maxillary incisor retraction with tip vs torque movements. *Am J Orthod Dentofacial Orthop* 1998; 114:520-5.
42. Lagravère MO, Carey J, Toogood RW, Major PW. Three-dimensional accuracy of measurements made with software on cone-beam computed tomography images. *Am J Orthod Dentofacial Orthop* 2008;134:112-16.
43. Ferreira PP, Torres M, Campos PS, Vogel CJ, de Araújo TM, Rebello IM. Evaluation of buccal bone coverage in the anterior region by cone-beam computed tomography. *Am J Orthod Dentofacial Orthop* 2013;144:698-704.
44. Yodthong N, Charoemratrote C, Leethanakul C. Factors related to alveolar bone thickness during upper incisor retraction. *Angle Orthod* 2013;83:394-401.
45. Bimstein E, Crevoisier RA, King DL. Changes in the morphology of the buccal alveolar bone of protruded permanent mandibular incisors secondary to orthodontic alignment. *Am J Orthod Dentofacial Orthop* 1990;97:427-30.
46. Björk A, Skieller V. Growth of the maxilla in three dimensions as revealed radiographically by the implant method. *Br J Orthod*. 1977 Apr;4(2):53-64.
47. Guo QY, Zhang SJ, Liu H, Wang CL, Wei FL, Lv T, Wang NN, Liu DX. Three-dimensional evaluation of upper anterior alveolar bone dehiscence after incisor retraction and intrusion in adult patients with bimaxillary protrusion malocclusion. *J Zhejiang Univ Sci B*. 2011;12:990-7.
48. Moshiri M, Scarfe WC, Hilgers ML, Scheetz JP, Silveira AM, Farman AG. Accuracy of linear measurements from imaging plate and lateral cephalometric images derived from cone-beam computed tomography. *Am J Orthod Dentofacial Orthop*. 2007;132:550-60.
49. Molen AD. Considerations in the use of cone-beam computed tomography for buccal bone measurements. *Am J Orthod Dentofac Orthop* 2010;137:S130-5.
50. Deguchi T, Takano-Yamamoto T, Yabuuchi T, Ando R, Roberts WE, Garetto LP. Histomorphometric evaluation of alveolar bone turnover between the maxilla and the mandible during experimental tooth movement in dogs. *Am J Orthod Dentofacial Orthop*. 2008;133:889-97.